

# Nomenclature and Classification of Lumbar Disc Pathology

Recommendations of the Combined Task Forces of the North American Spine Society, American Society of Spine Radiology, and American Society of Neuroradiology

David F. Fardon, MD,\* and Pierre C. Milette, MD†

## ■ Preface

Standardization of language is difficult, especially among those who have expert knowledge of the subject and clear understanding of what their own words mean. The difficulties must be overcome because deleterious effects ensue when we do not understand what one another's words mean. Existing dictionary definitions and previous efforts by experts have lacked the attention to detail and multidisciplinary consensus we brought to this work.

The North American Spine Society (NASS) initiated efforts to develop detailed definitions of lumbar disc pathology terms and has provided sustained support of the project. Independent efforts by neuroradiologists led the American Society of Spine Radiology (ASSR) and American Society of Neuroradiology (ASNR) to organize a task force of neuroradiologists and encourage liaison with the NASS group. The results are this document and improved communications between the societies.

The Board of Directors of NASS, and the Executive Committees of both ASSR and ASNR have endorsed this document, as has the Joint Section on Disorders of the Spine and Peripheral Nerves of the American Association of Neurological Surgeons (AANS) and Congress of Neurological Surgeons (CNS), and the CPT and ICD Coding Committee of the American Academy of Orthopaedic Surgeons (AAOS). Endorsement by other North American, European, and international societies is currently pending. This work is being simultaneously posted to the website of the journal *Spine* and on the ASSR and ASNR websites owing to special arrangements between the editors and publisher of *Spine* and the *American Journal of Neuroradiology* (AJNR).

The hope of all of us who have worked on this project is that it will ultimately improve the care of patients with spinal disorders.

David F. Fardon, MD, Chairperson, Clinical Task Force

Pierre C. Milette, MD, Chairperson, Imaging Task Force

## ■ Introduction

Physicians need reliable terms that describe normal and pathologic conditions of lumbar discs. Terms that can be interpreted accurately, consistently, and with reasonable precision are particularly important for communicating impressions gained from imaging for clinical diagnostic and therapeutic decision making. Although clear understanding of disc terminology between radiologists and clinicians is the focus of this work, such understanding can be critical, also, to patients, families, employers, insurers, jurists, social planners, and researchers.

In 1995, a multidisciplinary task force from the North American Spine Society (NASS) addressed deficiencies in standardization and current practice of the language defining conditions of the lumbar disc. It cited several documentations of the problem<sup>3–5,13,14,16,28</sup> and made detailed recommendations for standardization. Its work was published in a copublication of NASS and the American Academy of Orthopedic Surgeons (AAOS).<sup>15</sup> The work has not been otherwise endorsed by major organizations and has not been recognized as authoritative by radiology organizations. Many previous<sup>2,4,13,27–29,31,33,39,43–45,46,49</sup> and some subsequent<sup>12,19,22,24,25,26</sup> efforts have addressed the issues, but have been of more limited scope, and none has gained widespread compliance or formal endorsement.

Although the NASS 1995 effort has been the most comprehensive to date, it remains deficient in clarifying some controversial topics, lacking in its treatment of some issues, and does not provide recommendations for standardization of classification and reporting. To address the remaining needs, and in hopes of securing endorsement sufficient to result in universal standardization, joint task forces were formed by NASS, the American Society of Neuroradiology (ASNR), and the American Society of Spine Radiology (ASSR). This work is the product of those task forces.

A few general principles guided the generation of this document. The definitions should be based on the anatomy and pathology. Recognizing that some criteria, under some circumstances, may be unknowable to the observer, the definitions of diagnoses should not be dependent on or imply value of specific tests. The definitions of diagnoses should not define or imply external etiologic events such as trauma. The definitions of diagnoses should not imply relationship to symptoms. Defi-

\*Chairperson, Clinical Task Force. †Chairperson, Imaging Task Force.  
 See the appendix for a complete listing of the members of the Task Forces and consultants and advisors.

nitions of diagnoses should not define or imply need for specific treatment.

The task forces worked from a model that could be expanded from a primary purpose of providing understanding of reports of imaging studies. The result would provide a simple and relatively imprecise classification of diagnostic terms, based on pathology, which could be expanded, without contradiction, into more precise subclassifications. When reporting pathology, degrees of uncertainty would be labeled as such rather than compromising on the definitions of the terms.

All terms used in the classifications and subclassifications were to be defined, and those definitions would be adhered to throughout the model. For practical purpose, some existing English terms were given meanings different from those found in some contemporary dictionaries. The task forces would provide a list and classification of recommended terms, but, recognizing the nature of language practices, would discuss, and include in a glossary, commonly used and misused nonrecommended terms and nonstandard definitions.

Although the principles and most of the definitions of this document could be easily extrapolated to the cervical and dorsal spine, the focus is on the lumbar spine. While clarification of terms related to posterior elements and disorders related to dimensions of the spinal canal are also needed, this work is limited to discussion of the disc. Although it is not always possible to fully discuss the definition of anatomic and pathologic terms without some reference to symptoms and etiology, the definitions, themselves, stand the test of independence from etiology, symptoms, or treatment. Because of the focus on anatomy and pathology, this work does not define certain clinical syndromes that may be related to lumbar disc pathology.

Guided by those principles, this document provides a universally acceptable nomenclature that is workable for all forms of observation, that addresses contour, content, integrity, organization, and spatial relationships of the lumbar disc; and that serves a system of classification and reporting built on that nomenclature.

## ■ Recommendations

These recommendations present diagnostic categories and subcategories, intended for classification and the reporting of imaging studies. The terminology used throughout these recommended categories and subcategories remains consistent with detailed explanations given in the Discussion section and with the preferred definitions presented in the Glossary.

The diagnostic categories are based on pathology. Each lumbar disc can be classified in terms of one, and occasionally more than one, of the following diagnostic categories: Normal; Congenital/Developmental Variation; Degenerative/Traumatic; Infectious/Inflammatory; Neoplastic; and/or Morphologic Variant of Uncertain Significance (Table 1). Each diagnostic category can be subcategorized to various degrees of specificity accord-

**Table 1. General Classification of Disc Lesions\***

- Normal (excluding aging changes)
- Congenital/developmental variant
- Degenerative/traumatic lesion
  - Anular tear
  - Herniation
    - Protrusion/extrusion
    - Intravertebral
  - Degeneration
    - Spondylosis deformans
    - Intervertebral osteochondrosis
- Inflammation/infection
- Neoplasia
- Morphologic variant of unknown significance

\*Adapted with permission from Milette PC. Classification, diagnostic imaging, and imaging characterization of a lumbar herniated disc. *Radiol Clin North Am* 2000;38:1267-1292.

ing to the information available and purpose to be served. The data available for categorization may lead the reporter to characterize the interpretation as “possible,” “probable,” or “definite.”

### **Normal**

Normal defines young discs that are morphologically normal, without consideration of the clinical context and not inclusive of degenerative, developmental, or adaptive changes that could, in some contexts (*e.g.*, normal aging, scoliosis, spondylolisthesis) be considered clinically normal. However, the bilocular appearance of the adult nucleus resulting from the development of a central horizontal band of fibrous tissue is considered a sign of normal maturation.

### **Congenital/Developmental Variation**

The Congenital/Developmental Variation category includes discs that are congenitally abnormal or that have undergone changes in their morphology as an adaptation to abnormal growth of the spine such as from scoliosis or spondylolisthesis.

### **Degenerative/Traumatic**

Degenerative and/or Traumatic changes in the disc are included in a broad category that includes subcategories of Anular Tear; Herniation; and Degeneration. Characterization of this group of discs as Degenerative/Traumatic does not imply that trauma is necessarily a factor or that degenerative changes are necessarily pathologic as opposed to the normal aging process.

**Anular tears**, also properly called **anular fissures**, are separations between anular fibers, avulsion of fibers from their vertebral body insertions, or breaks through fibers that extend radially, transversely, or concentrically, involving one or many layers of the anular lamellae. The terms “tear” or “fissure” describe the spectrum of such lesions and do not imply that the lesion is consequent to trauma (Figure 1).

**Degeneration** may include any or all of real or apparent desiccation, fibrosis, narrowing of the disc space, diffuse bulging of the annulus beyond the disc space, extensive fissuring (*i.e.*, numerous anular tears), and mucic-

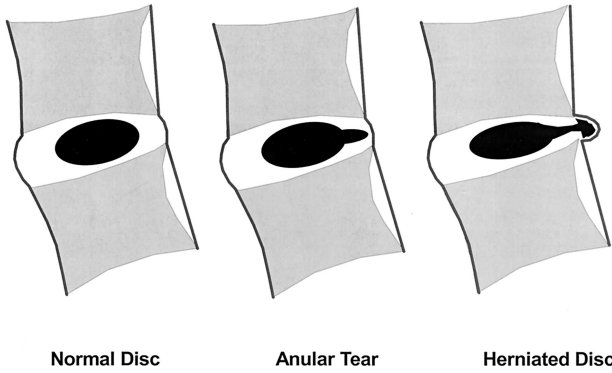


Figure 1. Schematic sagittal anatomic sections showing the differentiating features of an anular tear (radial tear in this case) and a disc herniation. The term “tear” is used to refer to a localized radial, concentric, or horizontal disruption of the annulus without associated displacement of disc material beyond the limits of the intervertebral disc space. Nuclear material is shown in black, and the annulus (internal and external) corresponds to the white portion of the intervertebral space. The same convention is used in Figures 2, 11, 12, and 13. (Adapted with permission from Milette PC. The proper terminology for reporting lumbar intervertebral disk disorders. *AJNR Am J Neuroradiol* 1997; 18: 1859–1866.)

nous degeneration of the annulus, defects and sclerosis of the endplates, and osteophytes at the vertebral apophyses. A disc demonstrating one or more of these degenerative changes can be further qualified into two subcategories: **spondylosis deformans**, possibly representing changes in the disc associated with a normal aging process; or **intervertebral osteochondrosis**, possibly the consequences of a more clearly pathologic process (Figure 2).

**Herniation** is defined as a localized displacement of disc material beyond the limits of the intervertebral disc space (Figure 1). The disc material may be nucleus, cartilage, fragmented apophyseal bone, anular tissue, or any combination thereof. The disc space is defined, craniad and caudad, by the vertebral body endplates (Figure 3) and, peripherally, by the outer edges of the vertebral ring apophyses, exclusive of osteophytic formations (Figure

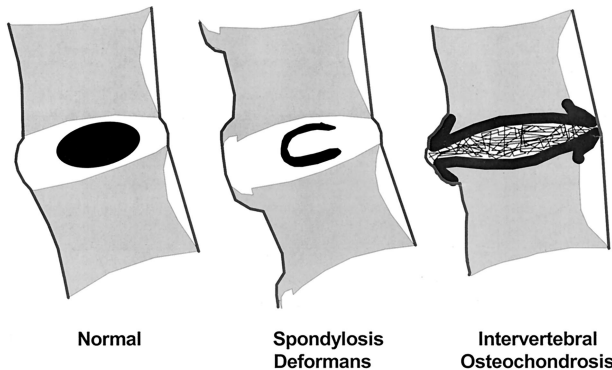
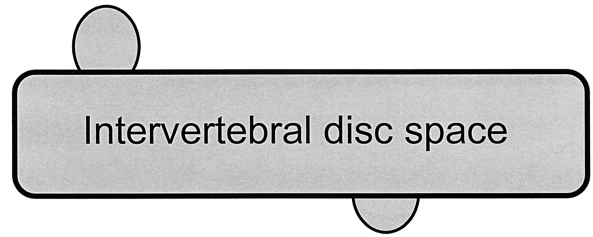


Figure 2. Schematic sagittal anatomic sections showing the differentiating characteristics of the normal disc, spondylosis deformans, and intervertebral osteochondrosis. The distinction between these three entities is usually possible on all imaging modalities, including conventional radiographs. (Adapted with permission.<sup>25</sup>)

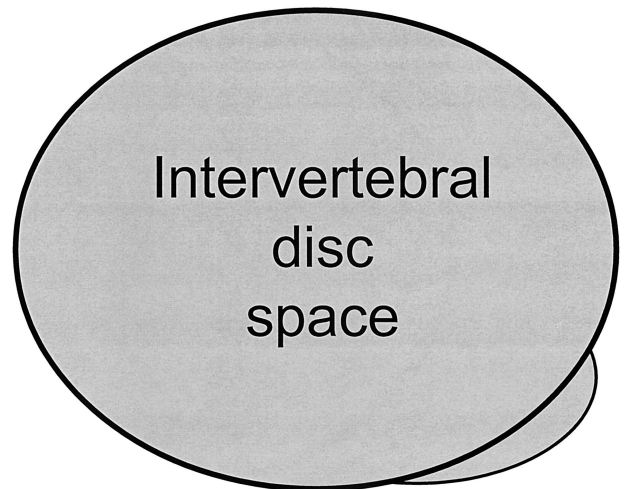


## Intravertebral Herniations

Figure 3. The term “herniated disc,” as defined in this work, refers to localized displacement of nucleus, cartilage, fragmented apophyseal bone, or fragmented anular tissue beyond the intervertebral disc space (disc space, interspace). The interspace is defined, craniad and caudad, by the vertebral body endplates. Two *intravertebral* herniations, one with an upward orientation and the other with a downward orientation with respect to the disc space, are illustrated schematically.

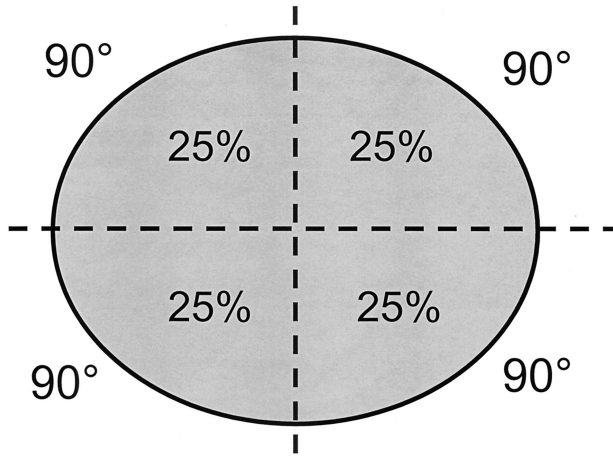
4). The term “localized” contrasts to “generalized,” the latter being arbitrarily defined as greater than 50% (180 degrees) of the periphery of the disc (Figure 5).

Localized displacement in the axial (horizontal) plane can be “focal,” signifying less than 25% of the disc circumference (Figure 6), or “broad-based,” meaning between 25 and 50% of the disc circumference (Figure 7). Presence of disc tissue “circumferentially” (50–100%) beyond the edges of the ring apophyses may be called “bulging” and is not considered a form of herniation (Figure 8), nor are diffuse adaptive alterations of disc



## Herniation

Figure 4. The interspace is defined, peripherally, by the edges of the vertebral ring apophyses, exclusive of osteophytic formations. The line drawing schematically illustrates a localized extension of disc material beyond the intervertebral disc space, in a left posterior direction, which qualifies as a disc herniation.

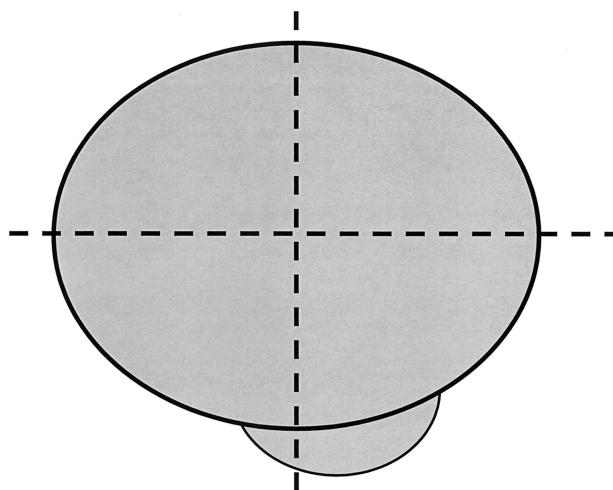


**Normal Disc**

Figure 5. For classification purposes, the intervertebral disc is considered as a two-dimensional round or oval structure having four 90° quadrants. By convention, a herniation is a "localized" process involving less than 50% (180°) of the disc circumference.

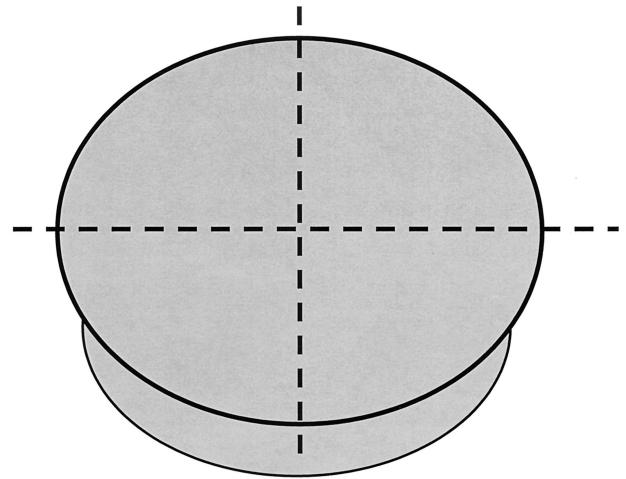
contour secondary to adjacent deformity as may be present in severe scoliosis or spondylolisthesis (Figure 9).

Herniated discs may take the form of protrusion or extrusion, based on the shape of the displaced material (Figure 10). **Protrusion** is present if the greatest distance, in any plane, between the edges of the disc material beyond the disc space is less than the distance between the edges of the base, in the same plane. The base is defined as the cross-sectional area of disc material at the outer margin of the disc space of origin, where disc material displaced beyond the disc space is continuous with disc material within the disc space. In the cranio-caudal direction, the length of the base cannot exceed, by definition, the height of the intervertebral space. **Extrusion** is present when, in at least one plane, any one distance



**Focal Herniation**

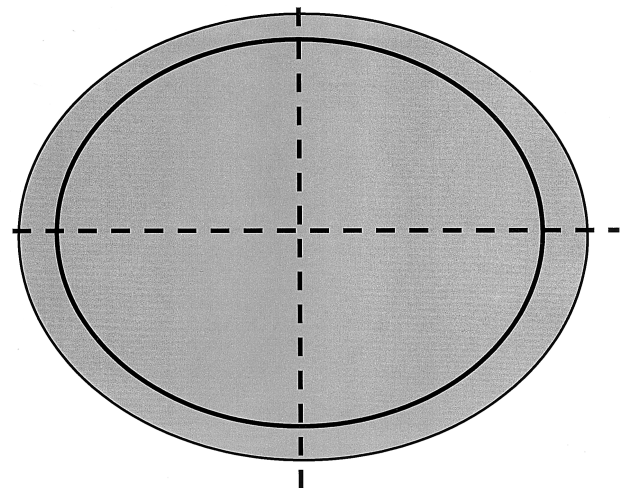
Figure 6. By convention, a "focal herniation" involves less than 25% (90°) of the disc circumference.



**Broad-based Herniation**

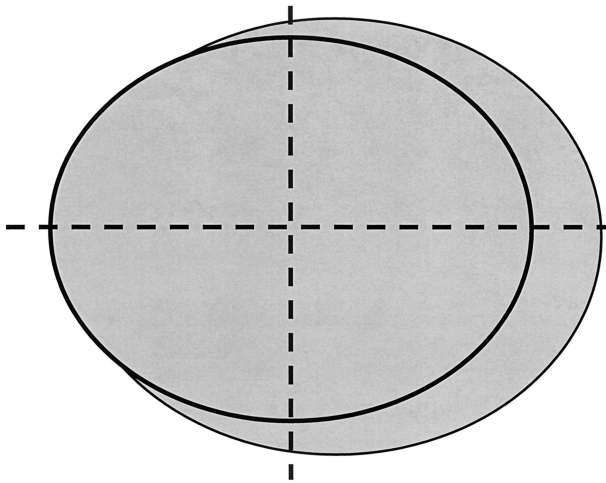
Figure 7. By convention, a "broad-based" herniation involves between 25% and 50% (90–180°) of the disc circumference.

between the edges of the disc material beyond the disc space is greater than the distance between the edges of the base, or when no continuity exists between the disc material beyond the disc space and that within the disc space (Figure 11). Extrusion may be further specified as **sequestration**, if the displaced disc material has lost completely any continuity with the parent disc (Figure 12). The term **migration** may be used to signify displacement of disc material away from the site of extrusion, regardless of whether sequestered or not (Figure 13). Because posteriorly displaced disc material is often constrained by the posterior longitudinal ligament, images may portray a disc displacement as a protrusion on axial sections



**"Symmetrical Bulging Disc"**

Figure 8. Symmetrical presence (or apparent presence) of disc tissue "circumferentially" (50–100%) beyond the edges of the ring apophyses may be described as a "bulging disc" or "bulging appearance" and is not considered a form of herniation. Furthermore, "bulging" is a descriptive term for the shape of the disc contour and not a diagnostic category.



### "Asymmetrical Bulging Disc"

Figure 9. Asymmetrical bulging of the disc margin (50–100%), such as what is found in severe scoliosis, is also not considered a form of herniation.

and an extrusion on sagittal sections, in which cases the displacement should be considered an extrusion. Herniated discs in the cranio-caudal (vertical) direction through a break in the vertebral body endplate are referred to as **intravertebral herniations**.

Disc herniations may be further specifically described as **contained**, if the displaced portion is covered by outer anulus, or **uncontained** when absent any such covering. Displaced disc tissues may also be described by location, volume, and content, as discussed later in this document. Table 2 lists the proposed categories for description and classification of disc herniations.

**Inflammation/Infection** The category of Inflammation/Infection includes infection, infection-like inflammatory discitis, and inflammatory response to spondyloarthropathy. It also includes inflammatory spondylitis of subchondral endplate and bone marrow manifested as Modic Type 1 magnetic resonance imaging (MRI) changes and usually associated with pathologic changes in the disc. To simplify the classification scheme, the

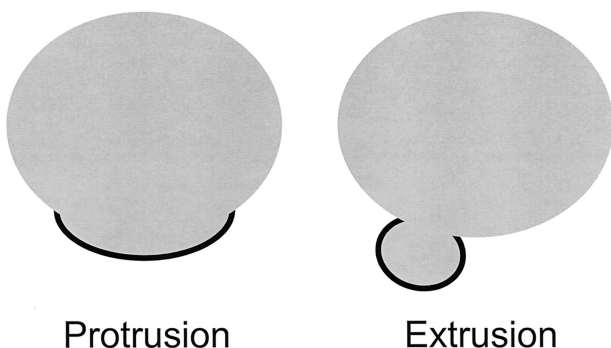


Figure 10. Herniated discs may take the form of protrusion or extrusion, based on the shape of the displaced material (see definitions in text).

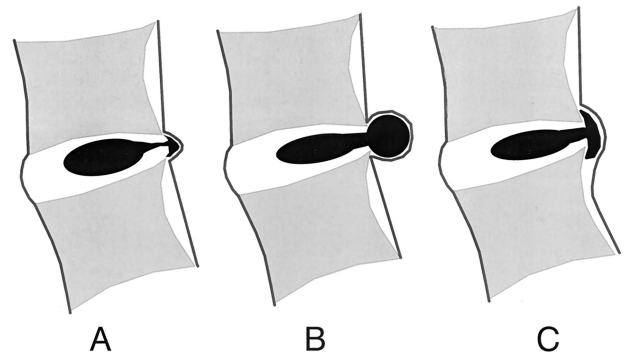


Figure 11. When a relatively large amount of disc material is displaced, distinction between protrusion (**A**) and extrusion (**B** or **C**) will generally only be possible on sagittal magnetic resonance (MR) sections or sagittal computed tomography (CT) reconstructions. **C**, Although the shape of the displaced material is similar to that of a protrusion, the greatest cranio-caudal diameter of the fragment is greater than the cranio-caudal diameter of its base at the level of the parent disc, and the lesion therefore qualifies as an extrusion. In any situation, the distance between the edges of the base, which serves as reference for the definition of protrusion and extrusion, may differ from the distance between the edges of the aperture of the anulus, which cannot be assessed on CT images and is seldom appreciated on MR images. In the cranio-caudal direction, the length of the base cannot exceed, by definition, the height of the intervertebral space. (Reprinted with permission from Milette PC. Classification, diagnostic imaging and imaging characterization of a lumbar herniated disc. *Radiol Clin North Am* 2000; 38:1267–1292.)

category is inclusive of disparate conditions; therefore, when data permit, the diagnosis should be subcategorized for appropriate specificity.

#### **Neoplasia**

Primary or metastatic morphologic changes of disc tissues caused by neoplasia are categorized as Neoplasia, with subcategorization for appropriate specificity.

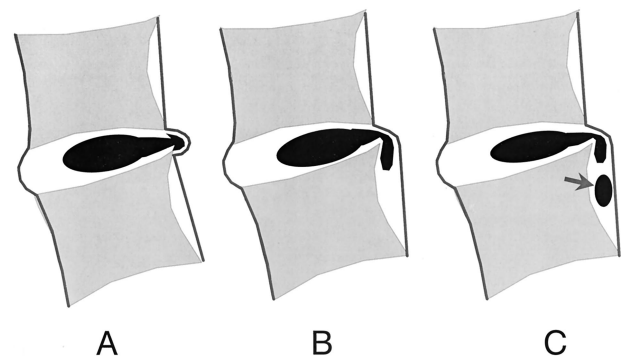


Figure 12. Schematic representation of various types of posterior central herniations. **A**, Small subligamentous herniation (or protrusion) without significant disc material migration. **B**, Subligamentous herniation with downward migration of disc material under the posterior longitudinal ligament (PLL). **C**, Subligamentous herniation with downward migration of disc material and *sequestered fragment* (arrow). (Reprinted with permission from Milette PC. Classification, diagnostic imaging and imaging characterization of a lumbar herniated disc. *Radiol Clin North Am* 2000; 38:1267–1292.)

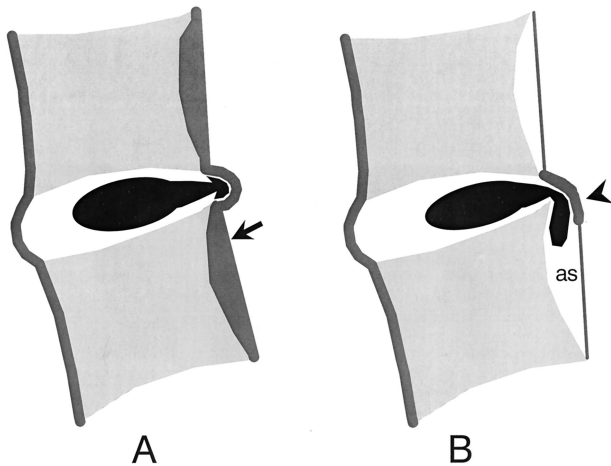


Figure 13. Relationship of typical posterior disc herniations with the posterior longitudinal ligament. **A**, Midline sagittal section: Unless very large, a posterior midline herniation usually remains entrapped underneath the deep layer of the PLL and sometimes a few intact outer anulus fibers joining with the PLL to form a “capsule.” The deep layer of the PLL (arrow) also attaches to the posterior aspect of the vertebral body so that no potential space is present underneath. **B**, Sagittal para-central section: The PLL extends laterally at the disc level (arrowhead) but, above and below the disc, an anterior epidural space (as), where disc fragments are frequently entrapped, is present between the lateral (peridural) membranes and the posterior aspect of the vertebral bodies. (Adapted with permission from Milette PC. Classification, diagnostic imaging and imaging characterization of a lumbar herniated disc. *Radiol Clin North Am* 2000;38:1267–1292.)

#### **Morphologic Variant of Unknown Significance**

Instances in which data suggest abnormal morphology of the disc but are not complete enough to warrant a diagnostic categorization can be categorized as Morphologic Variant of Unknown Significance.

#### **Discussion**

Acceptance and standardization occur most easily when recommendations are close to common practice. However, there are many contradictory views of common practice and some common practices are contradictory to our primary purpose, which is clear communication between those who interpret images and those who make clinical decisions.

This document defines a nomenclature that describes discs and leaves to the clinician the description of the patient. In so doing, however, this provides a nomencla-

ture that facilitates description of surgical or endoscopic findings as well as images; and also, with the caveat that it addresses only the morphology of the disc, it facilitates communication for patients, families, employers, insurers, and legal and social authorities, and permits accumulation of more reliable data for research.

#### **Normal**

Categorization of a disc as “Normal” means the disc is fully and normally developed and free of any changes of disease, trauma, or aging. Only the morphology, and not the clinical context, is considered. In common practice, people with a variety of harmless congenital or developmental variations of discs, minor bulging of anuli, anterior and lateral marginal vertebral body osteophytes, *etc.* are normal people. By this nomenclature and classification, however, such individual discs are not considered “normal.” Therein lies a significant difference of this method from what many would consider common practice. Some people are clinically “normal” even though they have morphologically abnormal discs.

#### **Anular Tears/Fissures**

There is general agreement about the various forms of loss of integrity of the anulus, such as radial, transverse, and concentric separations. Some, including the 1995 NASS document,<sup>15</sup> have recommended that such lesions be termed “fissures” rather than “tears,” primarily for fear that the word “tear” could be misconstrued as implying a traumatic etiology. Common practice, as documented by review of contemporary specialty journal literature<sup>12</sup> shows preference, among authors of various disciplines, for the term “tear,” and frequent synonymous use in the same articles of the terms “tear” and “fissure.”

In this instance, it is unwise to recommend contrary to ingrained common usage but wise to reiterate the caveat that the term “anular tear” does not imply traumatic etiology. In the case where a single, traumatic event is clearly the source of loss of integrity of a formally normal anulus, such as with documentation and findings of violent distraction injury, the term “rupture” of the anulus is appropriate, but use of the term “rupture” as synonymous with commonly observed tears or fissures is contraindicated. In conclusion, therefore, “anular tear” and “anular fissure” are both acceptable terms, can be used properly as synonyms, and do not imply that a significant traumatic event has occurred or that the etiology is known.

Some tears may have clinical relevance and others may be asymptomatic and inconsequential components of the aging process. Correlation of the characteristics of the tear with responses to discography and other clinically relevant observations may enable the observer to make such distinctions, but such is beyond the scope of this morphologically based definition and classification model.

**Table 2. Description of a Disc Herniation**

- Morphology
  - Protrusion
  - Extrusion
  - Intravertebral
- Containment
- Continuity
- Relation with PLL complex
- Volume
- Composition
- Location

### **Disc Degeneration**

Because there is confusion in differentiation of changes of pathologic degenerative processes in the disc from those of normal aging,<sup>8,30,38</sup> the classification category “Degenerative/Traumatic” includes all such changes, thus does not compel the observer to differentiate the pathologic from the normal consequences of aging. However, this model allows the observer with adequate data to present a more enlightening report by making such a distinction, with appropriate notation of the degree of confidence.

Perceptions of what constitutes the normal aging process of the spine have been greatly influenced by postmortem anatomic studies involving a limited number of specimens, harvested from cadavers from different age groups, with unknown past medical histories, and the presumption of absence of lumbar symptoms.<sup>7,9,17,20,23,34</sup> With such methods, pathologic changes are easily confused with consequences of normal aging. Resnick and Niwayama<sup>35</sup> emphasized the differentiating features of two degenerative processes involving the intervertebral disc, which had been previously described by Schmorl and Junghanns<sup>37</sup>: “spondylosis deformans,” which affects essentially the annulus fibrosus and adjacent apophyses, and “intervertebral osteochondrosis,” which affects mainly the nucleus pulposus and the vertebral body endplates, but also includes extensive fissuring (numerous tears) of the annulus fibrosus, which may be followed by atrophy (Figure 2). Although Resnick and Niwayama stated that the cause of the two entities was unknown, other scientific studies suggest that spondylosis deformans is the consequence of normal aging, whereas intervertebral osteochondrosis, sometimes also called “deteriorated disc,” results from a clearly pathologic, although not necessarily symptomatic, process.<sup>32,36,37,40,41</sup>

With normal aging, fibrous tissue replaces nuclear mucoid matrix, but the disc height is preserved and the disc margins remain regular.<sup>22</sup> Radial tears of the annulus are found only in a minority of postmortem examinations of individuals over 40 years of age,<sup>23</sup> so cannot be considered a usual consequence of aging. Slight symmetric bulging of the disc may occur in the elderly remodeling associated with osteoporosis.<sup>41</sup> On conventional radiographs and computed tomography (CT), small amounts of gas can be detected in some elderly individuals at the anular/apophyseal entheses, probably located in small transverse annular tears, and possibly signifying early manifestations of spondylosis deformans<sup>49</sup>; however, a large amount of gas in the central disc space is always pathologic and is a feature of intervertebral osteochondrosis.<sup>35</sup> Anterior and lateral marginal vertebral body osteophytes have been found in 100% of skeletons of individuals over 40, so are consequences of normal aging, whereas posterior osteophytes have been found in only a minority of skeletons of individuals over 80, so are not inevitable consequences of aging.<sup>32</sup> Endplate erosions with osteosclerosis and chronic reactive bone marrow changes also appear to be pathologic. Slight to mod-

erate decrease in central disc signal intensity found on T2-weighted MRIs can be a nonpathologic age-related observation but, if the result of a normal process, should be relatively uniform among all discs studied in the individual. Intervertebral osteochondrosis, or deteriorated disc, also sometimes called “chronic discopathy,” shows, on microscopic examination, total structural disorganization and general replacement of normal disc tissue by fibrosis. Radiographically, intervertebral osteochondrosis is characterized by narrowing of the intervertebral space, irregular disc contour often associated with bulging, multidirectional osteophytes often involving the central spinal canal and foramina, endplate erosions with reactive osteosclerosis, and chronic vertebral body bone marrow changes. On T2-weighted images, the central disc signal intensity is usually markedly decreased, and at distinct variance, to that seen in unaffected discs of the same individual. The distinction is made at the time of the reading and does not imply that early manifestations of a pathologic process are always distinguishable from changes of normal aging.

### **Herniated Disc**

The needs of common practice make necessary a diagnostic term that covers the various permutations of disc material displaced beyond the intervertebral disc space. Herniated disc, herniated nucleus pulposus, ruptured disc, prolapsed disc (used nonspecifically), protruded disc (used nonspecifically), and bulging disc (used nonspecifically) have all been used in the literature in various ways to denote imprecisely defined displacement of disc material beyond the interspace. The absence of clear understanding of the meaning of these terms and lack of definition of limits that should be placed on an ideal general term have created a great deal of confusion in clinical practice and in attempts to make meaningful comparisons of research studies.

For the general diagnosis of displacement of disc material, the single term that is most commonly used and creates least confusion is “herniated disc.” Attempts to avoid whatever confusion has been created by lack of definition of the term “herniated disc” have included the recommendation to substitute the term “disc material beyond the interspace” (DEBIT),<sup>4</sup> but that is more awkward and runs counter to common practice. “Herniated nucleus pulposus” (HNP) is inaccurate because materials other than nucleus (cartilage, fragmented apophyseal bone, fragmented annulus) are common components of displaced disc material.<sup>6,47,48</sup> “Rupture” casts an image of tearing apart and therefore carries more implication of traumatic etiology than “herniation,” which conveys an image of displacement rather than disruption.

Though “protrusion” has been used by some authors in a nonspecific general sense to signify any displacement, the term has a more commonly used specific meaning for which it is best reserved. “Prolapse,” which has been used as a general term, as synonymous with the specific meaning of protrusion, or to denote inferior mi-

gration of extruded disc material, is not commonly used and is best proscribed. The term “bulging disc” has been used to mean many things and has caused a great deal of confusion, as discussed below; therefore, its use as a general term to signify disc displacement should be avoided.

By exclusion of other terms, and by reasons of simplicity and common usage, “herniated disc” is the best general term to denote displacement of disc material. The term is appropriate to denote the general diagnostic category when referring to a specific disc and to be inclusive of various types of displacement when speaking of groups of discs. The term includes discs that may properly be characterized by more specific terms, such as “protruded disc” or “extruded disc.”

The term “herniated disc,” as defined in this work, refers to localized displacement of nucleus, cartilage, fragmented apophyseal bone, or fragmented anular tissue beyond the intervertebral disc space (disc space, interspace). The interspace is defined, cranial and caudal, by the vertebral body endplates and, peripherally, by the edges of the vertebral ring apophyses, exclusive of osteophytic formations. This definition was deemed more practical, especially for interpretation of imaging studies, than a pathologic definition requiring identification of disc material forced out of normal position through an anular defect. Displacement of disc material, either through a fracture in the bony endplate or in conjunction with displaced fragments of fractured walls of the vertebral body, may be described as “herniated,” disc, although such description should accompany description of the fracture so as to avoid confusion with primary herniation of disc material. Displacement of disc materials from one location to another within the interspace, as with intra-anular migration of nucleus without displacement beyond the interspace, is not considered herniation.

To be considered “herniated,” disc material must be displaced from its normal location and not simply represent an acquired growth beyond the edges of the apophyses, as is the case when connective tissues develop in gaps between osteophytic formations. Displacement, therefore, can only occur in association with disruption of the normal anulus or, as in the case of **intravertebral herniation** (Schmorl’s node), a break in the vertebral body endplate. Since details of the integrity of the anulus are often unknown, the distinction of herniation is usually made by observation of displacement of disc material beyond the edges of the ring apophyses that is “localized,” meaning less than 50% (180 degrees) of the circumference of the disc. Generalized, meaning greater than 50%, displacement of disc material beyond the ring apophyses, or adaptive changes of the apophyses and/or outer anulus to adjacent abnormality, such as may occur with scoliosis or spondylolisthesis, are not herniations. The 50% cut-off line is established by way of convention to lend precision to terminology and does not demarcate etiology, relation to symptoms, or treatment indications.

The term “bulge” refers to an apparent generalized extension of disc tissues beyond the edges of the apophyses.

Such bulging occurs in greater than 50% of the circumference of the disc and extends a relatively short distance, usually less than 3 mm, beyond the edges of the apophyses. “Bulge” describes a morphologic characteristic of various possible causes. Bulge is a term for an image that requires a differential diagnosis. Bulging is sometimes a normal variant (usually at L5-S1); can result from advanced disc degeneration or from vertebral body remodeling (as consequent to osteoporosis, trauma, or adjacent structural deformity); can occur with ligamentous laxity in response to loading or angular motion; can be an illusion caused by posterior central subligamentous disc protrusion; or can be an illusion from volume averaging (particularly with CT axial images).

Bulging, by definition, is not a herniation. Herniation is present if there is localized displacement of disc material, and not simply outward overlapping, as is the case with some types of bulging. Application of the term “bulging” to a disc does not imply any knowledge of etiology, prognosis, or need for treatment or necessarily imply the presence of symptoms.

A disc may have more than one herniation. A disc herniation may be present along with other degenerative changes, fractures or other abnormalities of adjacent bone, or other abnormalities of the disc. The term “herniated disc” does not imply any knowledge of etiology, relation to symptoms, prognosis, or need for treatment.

When data are sufficient to make the distinction, a herniated disc may be more specifically characterized as “protruded” or “extruded.” These distinctions are based on the shape of the displaced material. They do not imply knowledge of the mechanism by which the changes occurred and, thereby, differ from definitions that base the distinction on whether and how disc material has passed through a defect in the anulus.

**Protruded Discs** A disc is “protruded,” if the greatest plane, in any direction, between the edges of the disc material beyond the disc space is less than the distance between the edges of the base, when measured in the same plane. The term “protrusion” is only appropriate in describing herniated disc material, as discussed above.

Protrusions may be “focal” or “broad-based.” The distinction between focal and broad-based is arbitrarily set at 25% of the circumference of the disc. Protrusions with a base less than 25% (90 degrees) of the circumference of the disc are “focal.” If disc material is herniated so that the protrusion encompasses 25% to 50% of the circumference of the disc, it is considered “broad-based protrusion.”

**Extruded Discs** The term “extruded” is consistent with the lay language meaning of material forced from one domain to another through an aperture. With reference to a disc, the test of extrusion is the judgment that, in at least one plane, any one distance between the edges of the disc material beyond the disc space is greater than the distance between the edges of the base measured in the same plane; or when no continuity exists between the



disc material beyond the disc space and that within the disc space. Extruded disc material that has no continuity with the disc of origin may be further characterized as “sequestered.” A sequestered disc is a subtype of “extruded disc” but, by definition, can never be a “protruded disc.” Disc material that is displaced away from the site of extrusion, regardless of continuity, may be called “migrated,” a term that is useful for the interpretation of imaging studies because it is often impossible from images to know if continuity exists.

The use of the distinction between “protrusion” and “extrusion” is optional and some observers may prefer to use, in all cases, the more general term “herniation.” Further distinctions can often be made regarding containment, continuity, volume, composition, and location of the displaced disc material.

**Containment/Continuity** Herniated disc material can be “contained” or “uncontained.” The test of containment is whether the displaced disc tissues are wholly held within intact outer anulus. A disc with a “contained” herniation would not leak into the vertebral canal fluid that has been injected into the disc. Although the posterior longitudinal ligament and/or peridural membrane may partially cover extruded disc tissues, such discs are not considered “contained” unless the outer anulus is intact. Strictly speaking, containment refers to the integrity of the outer anulus covering the disc herniation. The technical limitations of currently available noninvasive imaging modalities (CT and MRI) usually preclude the distinction of a contained from an uncontained disc herniation. Discography does not allow one to distinguish a containing capsule consisting of both anular fibers and longitudinal ligament fibers from one consisting only of longitudinal ligament fibers, and essentially only allows one to separate a “leaking disc” from a “nonleaking disc.”

Displaced disc fragments are sometimes characterized as “free.” A “free fragment” is synonymous with a “sequestered fragment” and not the same as “uncontained,” as the latter refers only to the integrity of the outer anulus and has no inference as to the continuity of the displaced disc material with the parent disc. A fragment should be considered “free,” or “sequestered,” only if there is no remaining continuity of disc material between it and the disc of origin.

The term “migrated” disc or fragment refers to displacement of disc material away from the opening in the anulus through which the material has extruded. Some migrated fragments will be sequestered, but the term migrated refers only to position and not to continuity.

Referring to the posterior longitudinal ligament (PLL), some authors have distinguished displaced disc material as “subligamentous,” “extraligamentous,” “transligamentous,” or “perforated.” When the distinction between the outer anulus and the PLL is unclear and a fragment is under such a blended structure (sometimes called “capsule”), it has been called “subcapsular.” If the peridural membrane alone surrounds the displaced disc

material, the displacement is sometimes called “submembranous.” Such permutations of continuity, containment, and relationships to ligaments and membranes are refinements that may suit certain purposes but do not supersede the basic definition of disc herniation and the major subcategorizations of extrusion and protrusion.

**Volume and Composition of Displaced Material** A scheme to define the degree of canal compromise produced by disc displacement should be practical, objective, reasonably precise, and clinically relevant. A simple scheme that fulfills the criteria utilizes measurements taken from an axial section at the site of the most severe compromise. Canal compromise of less than one third of the canal at that section is “mild”; between one and two thirds is “moderate”; and over two thirds is “severe.” The same grading can be applied for foraminal involvement.

Such characterizations of volume describe only the cross-sectional area at one section and do not account for total volume of displaced material, proximity to, compression and distortion of neural structures, or other potentially significant features, which the observer may further detail by narrative description.

Composition of the displaced material may be characterized by such terms as “nuclear,” “cartilaginous,” “bony,” “calcified,” “ossified,” “collagenous,” “scarred,” “desiccated,” “gaseous,” or “liquefied.”

Clinical significance related to the observation of volume and composition depends on correlation with clinical data and cannot be inferred from morphologic data alone.

**Location** Bonneville proposed a useful and simple alpha-numerical system to classify, according to location, the position of disc fragments that have migrated in the horizontal or sagittal plane.<sup>2,3</sup> Using anatomic boundaries familiar to surgeons, Wiltse proposed another system.<sup>15,45</sup> Anatomic “zones” and “levels” are defined using the following landmarks: medial edge of the articular facets; medial, lateral, upper, and lower borders of the pedicles; and coronal and sagittal planes at the center of the disc (Figure 14). On the horizontal (axial) plane, these landmarks determine the boundaries of the “central zone,” the “subarticular zone,” the “foraminal zone,” the “extraforaminal zone,” and the “anterior zone,” respectively (Figure 15). On the sagittal (cranio-caudal) plane, they determine the boundaries of the “disc level,” the “infra-pedicular level,” the “pedicular level,” and the “supra-pedicular level,” respectively (Figure 16). The method is not as precise as drawings depict because borderlines such as the medial edges of facets and the walls of the pedicles are curved, but the method is simple, practical, and in common usage.

Moving from central to right lateral in the axial (horizontal) plane, location may be defined as “central,” “right central,” “right subarticular,” “right foraminal,” or “right extraforaminal.” The term “paracentral” is less precise than defining “right central” or “left central,”

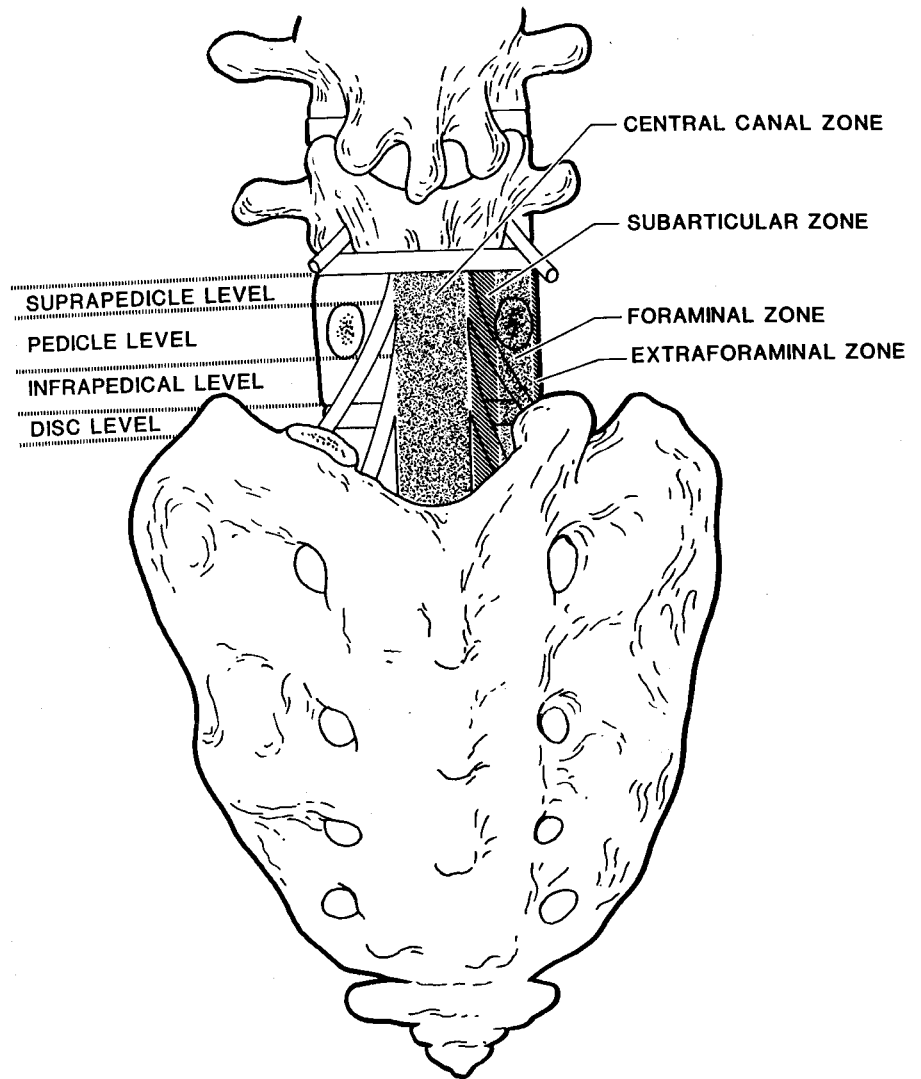


Figure 14. Coronal drawing illustrating the main anatomic "zones" and "levels". (Reprinted with permission.<sup>45</sup>)

but is useful in describing groups of discs that include both, or when speaking informally when the side is not significant. For reporting of image observations of a specific disc, "right central" or "left central" should supersede use of the term "paracentral." The term "far lateral" is sometimes used synonymously with "extraforaminal."

In the sagittal plane, location may be defined as "discal," "infra-pedicular," "supra-pedicular," or "pedicular." In the coronal plane, "anterior," in relationship to the disc, means ventral to the midcoronal plane of the centrum.

### ■ Reporting

When interpretations are made using clinical data, the nature of the clinical data and degree of confidence in them may be appropriate parts of the report. The report should distinguish interpretations that are made on purely morphologic grounds from those using clinical data. The sources of the morphologic data should be described.

Reports should classify each disc examined into broad diagnostic categories. Further specificity may be appro-

priate depending on the data and the purpose of the examination.

The ability to distinguish between various forms of herniation and between broad-based protrusion and bulging depends on the adequacy of available imaging data and the judgment of the interpreter. Likewise, knowing whether there is a thin thread of continuity between displaced disc material and disc of origin, or whether there is a small lapse in the integrity of the outer fibers of anulus, may not be possible, except by surgical observation.

Interpretations are made with various degrees of confidence. Statement of the degree of confidence is an important component of communication. The reporter should characterize the interpretation as "Definite" if there is no doubt, "Probable" if there is some doubt but the likelihood is greater than 50%, and "Possible" if there is reason to consider but the likelihood is less than 50%. The source and quality of the data are important qualifiers of the degree of confidence. It may be appropriate to characterize the interpretation with one degree of confidence based on morphologic criteria and another if clinical data are considered. If the interpreter has in-

In the axial image, the sagittal and parasagittal planes are called **zones**.

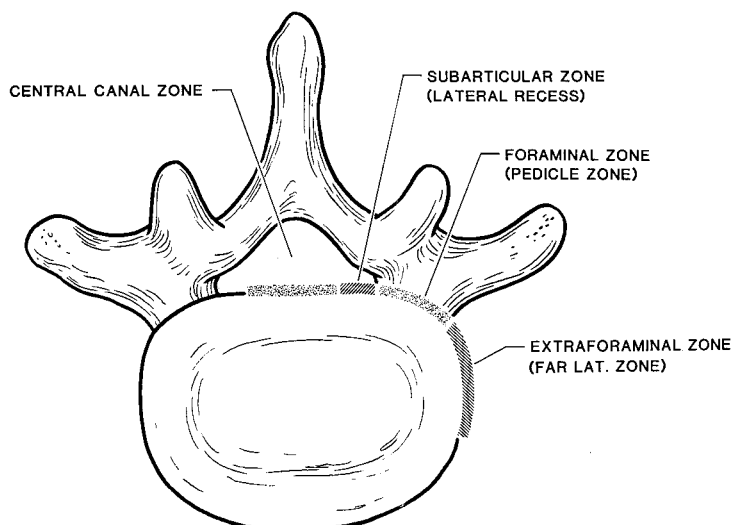


Figure 15. Schematic representation of the anatomic “zones” identified on axial images. The anterior zone (not illustrated) is delineated from the extraforaminal zone by an imaginary coronal line in the center of the vertebral body. (Adapted with permission.<sup>45</sup>)

formation enough to do so, he or she may further suggest that the imaging findings are, or are not, related to the patient’s symptoms, but the descriptive terms and diagnostic categories proposed in this model are not meant to infer any relationship to symptoms or need for treatment. Suggestions for additional studies to improve the level of confidence are often appropriate.

#### ■ Coding

The International Classification of Diseases (ICD) has been published under various names since 1900. Beginning in 1948, the World Health Organization (WHO) revised ICD approximately every 10 years. The 9th Revision (ICD-9)<sup>45</sup> was due for revision in 1987, but the first volume, the Tabular List, of the revision (ICD-10) was not prepared until 1992 and, as of 2000, has not been implemented in the United States. In practice, most coding in the United States follows a modification, the International Classification of Diseases, 9th Revision, Clinical Modification (ICD-9-CM),<sup>42</sup> which is officially updated in October of each year. Attempts to provide more specific coding for spinal disorders, such as that of the North American Spine Society,<sup>13</sup> have not been widely utilized because medical care providers and hospitals must use ICD-9-CM for reimbursement from government and private insurers.

A modification of WHO’s Fascicle V, Surgical Procedures, called the ICD-9-CM Procedure Classification,

published as Volume 3 to ICD-9-CM,<sup>42</sup> is used in the United States primarily by hospitals for coding procedures and complications that occur during hospitalization. Its validity has been studied with regard to spine procedures.<sup>10,11</sup> In the United States, for coding of examination, management, and procedures to care for spinal disorders, most physicians use the Current Procedural Terminology (CPT),<sup>1</sup> updated yearly by the American Medical Association.

In ICD-9-CM, the three-digit diagnosis code 722. is termed “Intervertebral disc disorders.” A fourth digit, following the decimal is used variously to specify site or type of pathology.

The first four subcategorizations (722.0, 722.10, 722.11, and 722.2) are for cervical, thoracic, lumbar, or site-unspecified “Displacement of intervertebral disc without myelopathy.” Listed as “Instructional Notations,” by way of examples of what may be included, are “Discogenic Syndrome, Herniation of Nucleus Pulposus, Intervertebral Disc Extrusion, Prolapse, Protrusion, Rupture, and Neuritis or Radiculitis due to displacement or rupture of intervertebral disc.” The fourth subcategorization, 722.3, is designated “Schmorl’s nodes.”

Subcategorizations 722.4, 722.5, and 722.6 are for “Degeneration of Intervertebral Disc” in the cervical, thoracic or lumbar, and unspecified regions, respectively. Instructional Notations specify inclusion of “degenera-

In the caudocranial direction visualized on sagittal and coronal images, we have chosen the term **levels**.




Figure 16. Schematic representation of the anatomic “levels” identified on cranio-caudal images. (Adapted with permission.<sup>45</sup>)

tive disc disease” and “narrowing of intervertebral disc or space.”

Subcategorization 722.7 is labeled “Intervertebral disc disorder with myelopathy.” It does not specify displacement of the disc. Fifth digits are added for regional location. Subcategorization 722.8 is labeled “Postlaminectomy syndrome.”

“Other and unspecified disc disorder” is the diagnostic label of 722.9, with Instructional Notations to include “calcification of intervertebral cartilage or disc” and “Discitis.” Observations of imaging variations of unknown significance can be coded 793.7, which ICD-9-CM describes as “Nonspecific abnormal findings on radiologic and other examination of body structure, Musculoskeletal.”

The International Classification of Diseases, 10th revision, lists intervertebral disc disorders under the “Other Dorsopathies” Section. Digits after the decimal for codes “M50.” and “M51.” provide separate codes for cervical or lumbar/thoracic “disc disorder with myelopathy,” “disc disorder with radiculopathy,” “other disc displacement,” “other disc degeneration,” “other disc disorders,” and “Schmorl’s nodes.”

Translation of the disc nomenclature recommended here into ICD-9-CM codes presents relatively little difficulty. Discs characterized herein as “herniated” should be coded under 722.0, 722.10, 722.11, or 722.2. A disc described as “bulging” without further specification as to the cause of the bulging should not be coded as a displacement, but, like other observations of uncertain significance as 722.9 “other and unspecified disc disorder” or as 793.7, “nonspecific abnormal findings on radiographic examination” (musculoskeletal). Intravertebral herniation (Schmorl’s node) should be coded 722.3. Although ICD-9-CM language characterizing “intervertebral disc disorder with myelopathy” does not specify that the disc is displaced, that is the logical implication, so it is better to code a displaced disc causing myelopathy as 722.7, rather than choose 722.0/1/2, which would introduce the contradictory language of “without myelopathy.” Various permutations of disc degeneration should be coded 722.4/5/6 and can be added, where appropriate, to codes that describe displacement. Nonspecific discitis and other not-elsewhere-classified disc disorders should be coded 722.9; except, of course, when specific pathogens, neoplastic disorders, or nondegenerative arthritides are known, in which case the specific diagnosis should be used, instead of, or in addition to, 722.9.

Translation of recommended terminology into ICD-10 is also fairly straightforward and follows the same principles. The International Classification of Diseases, 10th revision, takes the demands on clinical knowledge a step further by providing separate codes for “disc disorder with radiculopathy” (M50.1, M51.1), “disc disorder with myelopathy” (M50.0, M51.0), and “other disc displacement” (M50.2, M51.2). The emphasis is on the clinical neurologic status with “disorder” and “displacement” being used almost synonymously,

which contrasts with the aim of nomenclature to provide specificity to disc pathology and morphology. The differing axes of coding and terminology requirements are best bridged by assuming that disc herniations are coded as “other disc displacement” unless known to accompany radiculopathy or myelopathy, in which case they are best coded as “disc disorder with radiculopathy” or “disc disorder with myelopathy.” Like ICD-9-CM, ICD-10 provides specific codes for Schmorl’s nodes (M51.4) and for disc degeneration (M50.3, M51.3). ICD-10 provides separate codes for “other specified intervertebral disc disorders” (M50.8, M51.8) and for “intervertebral disc disorder, unspecified” (M50.9, M51.9).

Sciatic pain, lumbago, regional spinal pain syndromes, and radiculopathies and myelopathies not known to be caused by disc herniation are provided unique codes in both ICD-9-CM and ICD-10. Codes for disc disorders or displacements should only be used when a diagnosis of abnormal disc morphology is intended.

Procedural coding systems present little challenge to diagnostic nomenclature, since diagnoses are inferred but not defined by procedural codes. CPT provides codes for examination, management, and procedural services, including, in some instances the naming of diagnoses to help define the procedure; for example, operations to remove displaced disc material are characterized as “excision of herniated intervertebral disc” or as “discectomy,” as descriptors of certain procedures done through a laminotomy or laminectomy approach (63001-63048). Procedure 62287 is characterized as “aspiration procedure, percutaneous, of nucleus pulposus of intervertebral disc.”

## ■ Glossary

### Note

Some terms and definitions included in this Glossary are not recommended as preferred terminology but are included to facilitate interpretation of vernacular and, in some cases, improper use. Preferred definitions are listed first. Confusing or inaccurate alternative definitions are placed in brackets and designated as “Non-Standard.”

**aging disc** Disc demonstrating features of normal aging. Spondylosis deformans possibly represents the normal aging process.

**anterior displacement** Displacement of disc tissues beyond the disc space into the anterior zone.

**anterior zone** Peridiscal zone that is anterior to the midcoronal plane of the vertebral body.

**anulus, annulus (abbreviated form of annulus fibrosus)** A multilaminated ligament surrounding the periphery of each disc space, attaching, cranial and caudad, to endplate cartilage and ring apophyseal bone and blending centrally with nucleus pulposus. Note: Either anulus or annulus is correct spelling. *Nomina Anatomica* uses both forms, whereas *Terminologia Anatomica* states “anulus

fibrosus.”<sup>18,21</sup> Fibrosus has no correct alternative spelling; fibrosis has a different meaning and is incorrect in this context.

**asymmetric bulge** Presence of outer anulus beyond the plane of the disc space, more evident in one section of the periphery of the disc than another, but not sufficiently focal to be characterized as a protrusion. Note: Asymmetric bulge is a morphologic observation of various potential causes and is not a diagnosis. See: bulge.

**balloon disc (colloquial)** Diffuse displacement of nucleus through the vertebral endplate, commonly seen in severe osteoporosis.

**base (of displaced disc)** The cross-sectional area of disc material at the outer margin of the disc space of origin, where disc material beyond the disc space is continuous with disc material within the disc space. In the cranio-caudal direction, the length of the base cannot exceed, by definition, the height of the intervertebral space.

**broad-based protrusion** Protrusion of disc material extending beyond the outer edges of the vertebral body apophyses over an area greater than 25% (90 degrees) and less than 50% (180 degrees) of the circumference of the disc. See protrusion. Note: Broad-based protrusion refers only to discs in which disc material has displaced in association with localized disruption of the anulus and not to generalized (over 50% or 180 degrees) apparent extension of disc tissues beyond the edges of the apophyses. If the base is less than 25%, it is called “focal protrusion.” Apparent extension of disc material, formation of additional connective tissue between osteophytes, or overlapping of nondisrupted tissue beyond the edges of the apophyses of over 50% of the circumference of the disc may be described as bulging. See: bulging disc, focal protrusion.

**bulging disc, bulge (n), bulge (v).** 1. A disc in which the contour of the outer anulus extends, or appears to extend, in the horizontal (axial) plane beyond the edges of the disc space, usually over greater than 50% (180 degrees) of the circumference of the disc and usually less than 3 mm beyond the edges of the vertebral body apophyses. 2. (Non-Standard) [A disc in which the outer margin extends over a broad base beyond the edges of the disc space.] 3. (Non-Standard) [Mild, smooth displacement of disc, whether focal or diffuse.] 4. (Non-Standard) [Any disc displacement at the discal level.] Note: Bulging is an observation of the contour of the outer disc and is not a specific diagnosis. Bulging has been variously ascribed to redundancy of anulus secondary to loss of disc space height, ligamentous laxity, response to loading or angular motion, remodeling in response to adjacent pathology, unrecognized and atypical herniation, and illusion from volume averaging on CT axial images. Bulging may or may not represent pathologic change, physiologic variant, or normalcy. Bulging is not a form of herniation; discs known to be herniated

should be diagnosed as herniation or, when appropriate, as specific types of herniation. See: herniated disc, protruded disc, extruded disc.

**capsule** Combined fibers of anulus and posterior longitudinal ligament. Note: The interface between outer anulus and posterior longitudinal ligament can be indistinguishable, making useful the term “capsule” and the derivative “subcapsular,” which refers to disc tissue beneath the capsule.

**cavitation** Spaces, cysts, clefts, or cavities formed within the nucleus and inner anulus from disc degeneration.

**central zone** Zone within the vertebral canal between sagittal planes through the medial edges of each facet. Note: The center of the central zone is a sagittal plane through the center of the vertebral body. The zones to either side of the center plane are **right central** and **left central**, which are preferred terms when the side is known, as when reporting imaging results of a specific disc. When the side is unspecified, or grouped with both right and left represented, the term **paracentral** is appropriate.

**chondrosis** See intervertebral osteochondrosis.

**chronic disc herniation** Disc herniation with presence of calcification, ossification, or gas accumulation within the displaced disc material, suggesting that the herniation is not of recent origin. Note: The term implies the presence of calcification, ossification, or gas accumulation and should not be used for herniations of soft disc material, regardless of the duration of displacement. See: degenerated disc, hard disc.

**claw osteophyte** Bony outgrowth arising very close to the disc margin, from the vertebral body apophysis, directed, with a sweeping configuration, toward the corresponding part of the vertebral body opposite the disc.

**collagenized disc or nucleus** A disc in which the mucopolysaccharide of the nucleus has been replaced by fibrous tissue.

**communicating disc, communication (n), communicate (v)** Interruption in the periphery of the disc, so that fluid injected into the disc space could flow into the vertebral canal and thus into contact with displaced disc material. Note: Communication refers to the status of displaced disc tissues with reference to the parent disc. Containment refers to the integrity of the anulus as container of disc tissues. Uncontained, displaced disc tissues could be noncommunicating if the displaced tissue is sealed off by peridural membrane or by healing of the tear in the anulus.

**concentric tear** Tear or fissure of the anulus characterized by separation, or break, of anular fibers, in a plane roughly parallel to the curve of the periphery of the disc,

creating fluid-filled spaces between adjacent anular lamellae. See: radial tears, transverse tears.

**contained herniation, containment (n), contain (v)** 1. Displaced disc tissue that is wholly within an outer perimeter of uninterrupted outer anulus or capsule. 2. (Non-standard) [A disc with its contents mostly, but not wholly, within anulus or capsule.] 3. (Non-Standard) [A disc with displaced elements contained within any investiture of the vertebral canal.] Note: The preferred meaning encompasses disc tissues that are enclosed by distended portions of the outer anulus or composite of fibers of the anulus and posterior longitudinal ligament. A disc whose substance is less than wholly contained by anulus is uncontained, as is a disc outside of anular fibers but under a distinct posterior longitudinal ligament or peridural membrane. Designation of a disc as contained, or uncontained, should define the integrity of the anulus enclosing the disc, although such distinction may not be possible with currently available imaging methods.

**continuity** 1. Connection of displaced disc tissue by a bridge of disc tissue, however, thin, to tissue within the disc of origin. 2. (Non-Standard) [Connection of displaced displaced disc tissue by a substantial bridge of disc tissue to disc within the disc of origin]. 3. (Non-Standard) [Connection of displaced disc tissue by any tissue to disc tissue within the disc or origin.]

Note: Tenuous attachments, beyond recognition by most imaging methods, may have significance to the surgeon or endoscopist. Bridges of peridural membrane, or scar, do not represent continuity. See sequestration.

**Crock disc** See internal disc disruption syndrome.

**degenerated disc, degeneration (n), degenerate (v)** 1. Changes in a disc characterized by desiccation, fibrosis and cleft formation in the nucleus, fissuring and mucinous degeneration of the anulus, defects and sclerosis of endplates, and/or osteophytes at the vertebral apophyses. 2. Imaging manifestations commonly associated with such changes. 3. (Non-Standard) [Changes in a disc related to aging.] Note: Either of the first two definitions may be correct, depending on context. Clinical features must be considered to determine whether degenerative changes are pathologic and what may or may not have contributed to their development. The term degenerated disc, in itself, does not infer knowledge of cause, relationship to aging, presence of symptoms, or need for treatment. See intervertebral osteochondrosis, spondylosis, spondylosis deformans.

**degenerative disc disease** 1. A clinical syndrome characterized by manifestations of disc degeneration and symptoms thought to be related to those changes. 2. (Non-Standard) [Abnormal disc degeneration.] 3. (Non-Standard) [Imaging manifestations of degeneration greater than expected, considering the age of the patient]. Note: Causal connections between degenerative

changes and symptoms are often difficult clinical distinctions. The term carries implications of illness that may not be appropriate if the only manifestations are from imaging. The preferred term for description of imaging manifestations alone, or imaging manifestations of uncertain relationship to symptoms, is degenerated disc rather than degenerative disc disease.

**delamination** Separation of anular fibers along planes parallel to the periphery of the disc, thought to represent separation of laminated layers of the outer anulus fibrosus.

**desiccated disc** 1. Disc with reduced water content, usually primarily of nuclear tissues. 2. Imaging manifestations of reduced water content of the disc; or apparent reduced water content, as from alterations in the concentration of hydrophilic glycosaminoglycans.

**disc (disk)** Complex structure composed of nucleus, anulus, cartilaginous endplates, and vertebral body ring apophyseal attachments of anulus. Note: Most English language publications use the spelling disc more often than disk.<sup>12</sup> *Nomina Anatomica* designates the structures as “Disci intervertebrales” and *Terminologia Anatomica* as “discus intervertebralis/Intervertebral disc.”<sup>18,21</sup>

**disc of origin** Disc from which a displaced fragment originated. Syn: parent disc Note: Since displaced fragments often contain tissues other than nucleus, disc of origin is preferred to nucleus of origin. Parent disc is synonymous, but more colloquial.

**disc space** Space limited, craniad and caudad, by the endplates of the vertebrae and peripherally by the edges of the vertebral body ring apophyses exclusive of osteophytes. Syn: intervertebral disc space.

**disc space height** The distance between the planes of the endplates of the vertebrae craniad and caudad to the disc.

**discal level** Level of the vertebral canal between axial planes through the bony endplates of the vertebrae craniad and caudad to the disc.

**discogenic vertebral sclerosis** Increased bone density and calcification adjacent to the endplates of the vertebrae craniad and caudad to a degenerated disc, usually a manifestation of intervertebral osteochondrosis.

**displaced disc** A disc in which disc material is beyond the outer edges of the vertebral body ring apophyses (exclusive of osteophytes) of the craniad and caudad vertebrae, or, as in the case of intravertebral herniation, penetrated through the vertebral body endplate. Note: Displaced disc is a general term that does not imply knowledge of the underlying pathology, cause, relationship to symptoms, or need for treatment. The term includes, but is not limited to, disc herniation and disc migration. See: herniated disc, migrated disc.

**epidural membrane** See peridural membrane.

**extraforaminal zone** The zone beyond the sagittal plane of the lateral edges of the pedicles, having no well-defined lateral border. Syn: far lateral zone, far-out zone.

**extraligamentous** Posterior or lateral to the posterior longitudinal ligament. Note: Extraligamentous disc refers to displaced disc tissue that is located lateral, or posterior to, the posterior longitudinal ligament. If the disc has extruded through the posterior longitudinal ligament it is sometimes called “transligamentous” or “perforated,” and if through the peridural membrane, it is sometimes refined to “transmembranous.”

**extruded disc, extrusion (n), extrude (v)** A herniated disc in which, in at least one plane, any one distance between the edges of the disc material beyond the disc space is greater than the distance between the edges of the base in the same plane; or when no continuity exists between the disc material beyond the disc space and that within the disc space. Note: The preferred definition is consistent with the common language image of extrusion as an expulsion of material from a container through and beyond an aperture. Displacement beyond the outer annulus of disc material with any distance between its edges greater than the distance between the edges of the base distinguishes extrusion from protrusion. Distinguishing extrusion from protrusion by imaging is best done by measuring the edges of the displaced material and remaining continuity with the disc of origin, whereas relationship of the displaced disc material to the aperture through which it has passed is more readily observed surgically. Characteristics of protrusion and extrusion may coexist, in which case the disc should be subcategorized as extruded. Extruded discs in which all continuity with the disc of origin is lost may be further characterized as sequestered. Disc material displaced away from the site of extrusion may be characterized as migrated. See: herniated disc, migrated disc, protruded disc.

**fissure of annulus** Separations between annular fibers, avulsion of fibers from their vertebral body insertions, or breaks through fibers that extend radially, transversely, or concentrically, involving one or more layers of the annular lamellae. Syn: tear of annulus, torn annulus. Note: The terms fissure and tear are commonly used synonymously. Neither term implies any knowledge of etiology, relationship to symptoms, or need for treatment. Tear or fissure are both used to represent separations of annular fibers from causes other than sudden violent injury to a previously normal annulus, which can be appropriately termed “rupture of the annulus,” which, in turn, contrasts to the colloquial, nonstandard, use of the term “ruptured disc,” referring to herniation.

**focal protrusion** Protrusion of disc material so that the base of the displaced material is less than 25% (90 degrees) of the circumference of the disc. Note: Focal protrusion refers only to herniated discs that are not ex-

truded and do not have a base greater than 25% of the disc circumference. Protruded discs with a base greater than 25% are “broad-based protrusions.”

**foraminal zone** The zone between planes passing through the medial and lateral edges of the pedicles. Note: The foraminal zone is sometimes called the “pedicle zone,” which can be confusing because pedicle zone might also refer to measurements in the sagittal plane between the upper and lower surface of a given pedicle, which is properly called the “pedicle level.” The foraminal zone is also sometimes called “lateral zone,” which can be confusing because lateral zone can also mean extraforaminal zone or an area including both the foraminal and extraforaminal zones.

**free fragment** 1. A fragment of disc that has separated from the disc of origin and has no continuous bridge of disc tissue with disc tissue within the disc of origin. Syn: sequestered disc 2. (Non-Standard) [A fragment that is not contained within the outer perimeter of the annulus.] 3. (Non-Standard) [A fragment that is not contained within annulus, posterior longitudinal ligament, or peridural membrane.] Note: Sequestered disc and free fragment are virtually synonymous. When referring to the condition of the disc, categorization as extruded with subcategorization as sequestered is preferred, whereas free fragment or sequestrum is appropriate when referring specifically to the fragment.

**hard disc** Disc displacement in which the displaced portion has undergone calcification or ossification and may be intimately associated with apophyseal osteophytes. Note: The term hard disc is most often used in reference to the cervical spine to distinguish chronic hypertrophic and reactive changes in the periphery of the disc from acute extrusion of soft, predominantly nuclear tissue. See: chronic disc herniation.

**herniated disc, herniation (n), herniate (v)** 1. Localized displacement of disc material beyond the normal margins of the intervertebral disc space. 2. (Non-Standard) [Any displacement of disc tissue beyond the disc space]. Note: Localized means, by way of convention, less than 50% (180 degrees) of the circumference of the disc. Disc material may include nucleus, cartilage, fragmented apophyseal bone, or fragmented annular tissue. The normal margins of the intervertebral disc space are defined, cranial and caudad, by the vertebral body endplates and peripherally by the edges of the vertebral body ring apophyses, exclusive of osteophytic formations. Herniated disc generally refers to displacement of disc tissues through a disruption in the annulus, the exception being intravertebral herniations (Schmorl’s nodes) in which the displacement is through vertebral endplate. Herniated discs in the horizontal (axial) plane may be further subcategorized as protruded or extruded. Herniated disc is sometimes referred to as “herniated nucleus pulposus,” but the term herniated disc is preferred because displaced disc tissues often include cartilage, bone fragments, or

anular tissues. The term “ruptured disc” is used synonymously with herniated disc, but is more colloquial and can be easily confused with violent, traumatic rupture of the annulus or endplate. The term “prolapse” has also been used as a general term for disc displacement, but its use has been inconsistent. The term herniated disc does not infer knowledge of cause, relation to injury or activity, concordance with symptoms, or need for treatment.

**herniated nucleus pulposus (HNP)** See herniated disc.

**high intensity zone (HIZ)** Area of high signal intensity on T2-weighted magnetic resonance images of the disc, usually referring to the outer annulus. Note: High intensity zones within the posterior annular substance may reflect fissure or tear of the annulus, but do not imply knowledge of etiology, concordance with symptoms, or need for treatment.

**infra-pedicular level** The level between the axial planes of the inferior edge of the pedicle cranial to the disc in question and the inferior endplate of the vertebral body above. Syn: superior vertebral notch.

**internal disc disruption** Disorganization of structures within the disc space

**internal disc disruption syndrome** Internal disc disruption associated with symptoms, which are thought, on clinical grounds, to be caused by the disruption. Syn: Crock disc.

**interspace** See disc space.

**intervertebral chondrosis** See intervertebral osteochondrosis.

**intervertebral disc** See disc.

**intervertebral disc space** See disc space.

**intervertebral osteochondrosis** Degenerative process of the spine involving the vertebral body endplates, the nucleus pulposus, and the annulus fibrosus, which is characterized by disc space narrowing, vacuum phenomenon, and vertebral body reactive changes. Syn: deteriorated disc, chronic discopathy, osteochondrosis.

**intra-anular displacement** Displacement of central, predominantly nuclear, tissue to a more peripheral site within the disc space, usually into a fissure in the annulus. Syn: (Non-Standard) [intra-anular herniation], [intradiscal herniation]. Note: Intra-anular displacement is distinguished from disc herniation, in that herniation of disc refers to displacement of disc tissues beyond the disc space. Intra-anular displacement is a form of internal disruption. When referring to intra-anular displacement, it is best not to use the term “herniation” in order to avoid confusion with disc herniation.

**intra-anular herniation (Non-Standard)** See intra-anular displacement.

**intradiscal herniation (Non-Standard)** See intra-anular displacement.

**intradural herniation** A disc from which displaced tissue has penetrated, or become enclosed by, the dura so that it lies within the thecal sac.

**intravertebral herniation** A disc in which a portion of the disc is displaced through the endplate into the centrum of the vertebral body. Syn: Schmorl’s node.

**lateral membrane** See peridural membrane.

**lateral recess** See subarticular zone.

**lateral zone** See foraminal zone.

**limbus fracture** Traumatic separation of a segment of bone from the edge of the vertebral ring apophysis at the site of annular attachment. Note: Limbus fractures of various types may be accompanied by disc herniation, usually by either focal or broad-based protrusion. They may occur into the anterior zone or posteriorly into the zones where they may compress neural tissues.

**limbus vertebrae** Separation of a segment of rim of vertebral body ring apophysis. Note: Limbus vertebrae may result from fracture or from developmental abnormalities. Limbus vertebrae is commonly seen in patients who have had Scheuermann’s disease. The lesions may be called “rim lesions.” The term is derived from the Latin nominative limbus and genitive modifier vertebrae, thus is singular.

**marginal osteophyte** Osteophyte that protrudes from and beyond the outer perimeter of the vertebral endplate apophysis.

**marrow changes (of vertebral body)** See vertebral body marrow changes (Modic classification).

**migrated disc, migration (n), migrate** 1. Herniated disc in which a portion of extruded disc material is displaced away from the tear in the outer annulus through which it has extruded. 2. (Non-Standard) [A herniated disc with a free fragment or sequestrum beyond the disc level.] Note: Migration refers to the position of the displaced disc material, rather than to its continuity with disc tissue within the disc of origin; therefore, it is not synonymous with sequestration.

**Modic Type 1,2,3** See vertebral body marrow changes.

**nonmarginal osteophyte** Osteophyte occurs at sites other than the vertebral endplate apophysis. See: marginal osteophyte.

**normal disc** 1. A fully and normally developed disc with no changes attributable to trauma, disease, degeneration, or aging. The bilocular appearance of the adult nucleus is considered a sign of normal maturation. 2. (Non-Standard) [A disc that may contain one or more morphologic variants which would be considered normal given the clinical circumstances of the patient.].



Note: Many congenital and developmental variations may be normal in that they are not associated with symptoms, certain adaptive changes in the disc may be normal considering adjacent pathology, and certain degenerative phenomena may be normal given the patient's age; however, classification and reporting for medical purposes is best served if such discs are not considered normal. What is clinically normal for a given patient is a clinical judgment independent of the need to describe any variation in the disc itself.

**nucleus of origin** The central, nuclear portion of the disc of reference, usually used to reference the disc from which tissue has been displaced. Syn: parent nucleus, disc of origin.

**osteochondrosis** See intervertebral osteochondrosis.

**osteophytes** Focal hypertrophy of bone surface and/or ossification of soft tissue attachments to the bone.

**paracentral** In the right or left central zone of the vertebral canal. See central zone. Note: The terms right central or left central are preferable when speaking of a single site when the side can be specified, as when reporting the findings of imaging procedures. Paracentral is appropriate if the side is not significant or when speaking of mixed sites.

**parent disc** See disc of origin.

**parent nucleus** See nucleus of origin, disc of origin.

**pedicular level** The level between axial planes through the upper and lower edges of the pedicle. Note: The pedicular level may be further designated with reference to the disc in question as "pedicular level above" or "pedicular level below." Distinction should be made between designation of the pedicular level in the sagittal plane and the "foraminal zone" which is defined by the planes of the medial and lateral walls of the pedicles in the axial plane. Syn: peduncular level.

**peduncular** See pedicular.

**perforated** (Non-Standard) See transligamentous.

**peridural membrane** A delicate, translucent membrane that attaches to the undersurface of the deep layer of the posterior longitudinal ligament, and extends laterally and posteriorly, encircling the bony spinal canal outside the dura. The veins of Batson's plexus lie on the dorsal surface of the peridural membrane and pierce it ventrally. Syn: lateral membrane, epidural membrane.

**prolapsed disc, prolapse (n), prolapse (v)** (Nonstandard) 1. A herniated disc in which disc tissue has protruded or extruded at the level of the disc and below into the suprapedicular level. 2. (Nonstandard) [Any herniated disc.] Note: The term prolapse is not used widely outside of medicine. Medically, it usually means to fall out and down, as with prolapse of the rectum or uterus. Analogy to the disc would apply most closely to disc tissue that

has displaced beyond the disc space into the suprapedicular zone. It has been used often, nonspecifically, as synonymous with herniation. Prolapse is not a recommended term for description of disc displacement.

**protruded disc, protrusion (n), protrude (v)** 1. A herniated disc in which the greatest plane, in any direction, between the edges of the disc material beyond the disc space is less than the distance between the edges of the base, when measured in the same plane. 2. (Non-Standard) [A disc in which disc tissue beyond the disc space is contained within intact anulus]. 3. (Non-Standard) [Any, or unspecified type of, disc herniation.] Note: The test of protrusion is that there must be a localized (less than 50% or 180° of the circumference of the disc) displacement of disc tissue so that the distance between the corresponding edges of the displaced portion must not be greater than the distance between the edges of the base. A disc that has broken through the outer anulus at the apex, but maintains a broad continuity at the base, is protruded and uncontained. While sometimes used as a general term in the way herniation is defined here, the use of the term protrusion is best reserved for subcategorization of herniations meeting the above criteria. See: extruded disc.

**radial fissure or tear** Disruption of anular fibers extending from the nucleus outward toward the periphery of the anulus, usually in the craniad-caudad (vertical) plane, though, at times, with occasional horizontal (transverse) components. Note: Occasionally a radial fissure extends in the transverse plane to include avulsion of the outer layers of anulus from the apophyseal ring. See: concentric tears, radial tears.

**rim lesion** See limbus vertebrae.

**ruptured anulus** Disruption of the fibers of the anulus by sudden violent injury. Note: Separation of fibers of the anulus from degeneration, repeated minor trauma, other nonviolent etiology, or when injury is simply a defining event in a degenerative process should be termed fissure or tear of the anulus. Rupture is appropriate when there is other evidence of sudden violent injury to a previously normal anulus. Ruptured anulus is not synonymous with ruptured disc, which is a colloquial equivalent of disc herniation.

**ruptured disc, rupture** (Non-Standard) 1. A herniated disc. 2. (Non-Standard) [A disc in which the anulus has lost its integrity.] See herniated disc, ruptured anulus. Note: Ruptured disc is used colloquially to encompass the same nonspecific meaning as the preferred term herniated disc. The common, nonmedical meaning of rupture, to break apart or burst, and the medical use of rupture in the sense of complete tears of ligament or tendon are analogous to the anulus disrupted by violent injury, which may be appropriately characterized as "ruptured anulus," which is not synonymous with "ruptured disc."

**scarred disc** See collagenized disc.

**Schmorl's node** See intravertebral herniation.

**sequestered disc, sequestration (n), sequestrate (v); (var: sequestered disc)** An extruded disc in which a portion of the disc tissue is displaced beyond the outer annulus and maintains no connection by disc tissue with the disc of origin. Note: An extruded disc may be subcategorized as "sequestered" if no disc tissue bridges the displaced portion and the tissues of the disc of origin. If there is a fragment of disc tissue that is not continuous with parent nucleus, but still contained, even in part, by annular tissues the disc may be characterized as protruded or extruded, but not as sequestered. If even a tenuous connection by disc tissue remains between a displaced fragment and disc of origin, the disc is not sequestered. If a displaced fragment has no connection with the disc of origin, but is contained within peridural membrane or under a portion of posterior longitudinal ligament that is not intimately bound with the annulus of origin, the disc is considered sequestered. If the fragment is attached to the disc of origin by scar, or other nondiscal tissue, or is merely in apposition to the disc of origin and not connected by disc tissue, it is considered sequestered. Sequestered and sequestered are used interchangeably.

**sequestrum** Disc tissue that has become displaced from the disc space of origin and lacks any continuity with disc material within the disc space of origin. Syn: disc fragment. See: sequestered disc. Note: Sequestrum refers to the isolated fragment itself, whereas sequestered disc defines the condition of the disc.

**spondylitis** Inflammatory disease of the spine, other than degenerative disease. Note: Spondylitis usually refers to noninfectious inflammatory spondyloarthropathies.

**spondylosis** 1. Spondylosis deformans, for which spondylosis is a shortened form. 2. (Non-Standard) Any degenerative changes of the spine that include osteophytic enlargement of apophyseal bone. Note: Spondylosis deformans has specific characteristics that distinguish it from intervertebral osteochondrosis. Both processes include vertebral body osteophytes. The term "spondylosis" is often used in general as synonymous with "degeneration" which would include both processes, but such usage is confusing, so it is best that "degeneration" be the general term and "spondylosis deformans" a specifically defined subclassification of degeneration. See: degeneration, intervertebral osteochondrosis, spondylosis deformans.

**spondylosis deformans** Degenerative process of the spine involving essentially the annulus fibrosus and characterized by anterior and lateral marginal osteophytes arising from the vertebral body apophyses, while the intervertebral disc height is normal or only slightly decreased. See: degeneration, spondylosis.

**subannular herniation** (Non-Standard) Disc herniation in which a displaced portion is contained by annulus. Syn: contained herniation. Note: Subannular describes a herniated disc that is contained by annulus and is not synonymous with the nonherniated "intra-annular displacement." See intra-annular displacement.

**subarticular zone** The zone, within the vertebral canal, sagittally between the plane of the medial edges of the pedicles and the plane of the medial edges of the facets, and coronally between the planes of the posterior surfaces of the vertebral bodies and the under anterior surfaces of the superior facets. Syn: lateral recess, posterolateral zone Note: The subarticular zone cannot be precisely delineated because the structures that define the planes of the zone are irregular. The lateral recess refers more appropriately to the space beneath the facet at the pedicular level than as synonymous with the entire subarticular zone.

**subcapsular** Beneath the composite of annulus and posterior longitudinal ligament. See subligamentous.

**subligamentous** Beneath the posterior longitudinal ligament. Note: Though the distinction between outer annulus and posterior longitudinal ligament may not always be identifiable, subligamentous has meaning distinct from subannular, when the distinction can be made. When the distinction cannot be made, subcapsular is appropriate. Subligamentous contrasts to extraligamentous, transligamentous, or perforated. See extraligamentous, transligamentous.

**submembranous** Enclosed within peridural membrane. Note: With reference to displaced disc material, characterization of a herniation as submembranous usually infers that the displaced portion is extruded beyond annulus and posterior longitudinal ligament so that only the peridural membrane invests it. The peridural membrane may also enclose material injected into a leaking disc, hematoma, or abscess. See: transmembranous.

**supra-pedicular level** The level within the vertebral canal between axial planes of the superior endplate of the vertebra caudad to the disc space in question and the superior margin of the pedicle of that vertebra. Syn: inferior vertebral notch.

**syndesmophytes** Thin and vertically oriented bony outgrowths extending from one vertebral body to the next and representing ossification within the outer portion of the annulus fibrosus.

**tear of annulus, torn annulus** See fissure of annulus and rupture of annulus.

**traction osteophytes** Bony outgrowth arising from the vertebral body apophysis, 2–3 mm above or below the edge of the intervertebral disc, projecting in a horizontal direction.

**transligamentous** Displacement, usually extrusion, of disc material through the posterior longitudinal ligament. Syn: perforated. See also extraligamentous, transmembranous.

**transmembranous** Displacement, usually of extruded disc material, through the peridural membrane.

**transverse tear** Tear or fissure of the anulus, running in the axial plane (horizontally), usually limited to rupture of the outer anular attachments to the ring apophysis. Note: Transverse tears are usually small and are located at the junction of the anulus and ring apophysis. They may fill with gas and, thereby, become detectable on radiographs or CT. They may be early manifestations of spondylosis deformans. More extensive radial tears may have a transverse component. See: concentric tears, radial tears.

**uncontained** 1. Displaced disc material that is not contained by uninterrupted outer anulus. 2. (Non-Standard) [A disc in which a substantial portion of the displaced portion of the disc is outside of disc tissues.] 3. (Non-Standard) [A disc in which a displaced portion is wholly outside of disc tissues]. 4. (Non-Standard) [A disc in which a displaced fragment is not contained within disc tissues, ligament, or membrane]. See discussion under contained disc.

**undisplaced disc** A disc in which all disc material is within the intervertebral disc space.

**vacuum disc** A disc with imaging characteristics suggestive of gas in the disc space, usually a manifestation of disc degeneration.

**vertebral body marrow changes (Modic's classification)** Reactive vertebral body modifications associated with disc inflammation and degenerative disc disease, as seen on MR images. Type 1 refers to decreased signal intensity on T1-weighted spin-echo images and increased signal intensity on T2-weighted images, indicating bone marrow edema associated with acute or subacute inflammatory changes. Types 2 and 3 indicate chronic changes. Type 2 refers to increased signal intensity on T1-weighted images and isointense or increased signal intensity on T2-weighted images, indicating replacement of normal bone marrow by fat. Type 3 refers to decreased signal intensity on both T1 and T2-weighted images, indicating reactive osteosclerosis.

**vertebral notch (inferior)** Incisura of the upper surface of the pedicle corresponding to the lower part of the foramen (supra-pedicular level).

**vertebral notch (superior)** Incisura of the under surface of the pedicle corresponding to the upper part of the foramen (infra-pedicular level).

## References

- American Medical Association, Current Procedural Terminology Editorial Panel. Current Procedural Terminology 2000. Chicago: American Medical Association, 2000.
- Bonneville JF. Plaidoyer pour une classification par l'image des hernies discales lombaires: la carte-image. *Rev Im Med* 1990;2:557-60.
- Bonneville JF, Dietemann JL. L'imagerie dans les sciatiques; *Rev Prat (Paris)* 1992;42:554-66.
- Brant-Zawadzki MN, Jensen MC. Imaging corner: Spinal nomenclature. Inter- and intra-observer variability in interpretation of lumbar disc abnormalities: A comparison of two nomenclatures. *Spine* 1995;20:388-90.
- Breton G. "Is that a bulging disc, a small herniation, or a moderate protrusion?" *Can Assoc Radiol J* 1991;42:318.
- Brock M, Patt S, Mayer HM. The form and structure of the extruded disc. *Spine* 1992;17:1457-61.
- Coventry, MB, Ghormley RK, Kernohan JW. The intervertebral disc: its microscopic anatomy and pathology. *J Bone Joint Surg* 1945;27:105-112.; 233-247.
- Czervionke LF. Lumbar intervertebral disc disease. *Neuroimaging Clin North Am* 1993;3:465-85.
- Eckert C, Decker A. Pathological studies of the intervertebral discs. *J Bone Joint Surg* 1947;29:447-54.
- Faciszewski T, Broste SK, Fardon D. Quality of data regarding diagnoses of spinal disorders in administrative databases. *J Bone Joint Surg [Am]* 1997; 79:1481-8.
- Faciszewski T, Johnson L, Noreen C, et al. Administrative databases' complication coding in anterior spinal fusion procedures. What does it mean? *Spine* 1995;20:1783-8.
- Fardon DF. Disc nomenclature: Current journal practices. Poster presentation, American Orthopaedic Association 110th Annual Meeting, Boca Raton, FL, June 11, 1997.
- Fardon DF, Balderston RA, Garfin SR, et al. Disorders of the Spine, A Coding System for Diagnoses. Philadelphia: Hanley and Belfus, 1991:20-2.
- Fardon DF, Balderston RA, Garfin SR, et al. Terms used for diagnosis by English speaking spine surgeons. *Spine* 1993;18:1-4.
- Fardon DF, Herzog RJ, Mink JH, et al. Nomenclature of lumbar disc disorders. In: Garfin SR, Vaccaro AR, eds. *Orthopaedic Knowledge Update—Spine*. Rosemont, IL: American Academy of Orthopaedic Surgeons, 1997: A3-A14.
- Fardon DF, White AH, Wiesel S. Diagnostic terms and conservative treatments favored for lumbar disorders by spine surgeons in North America. Presented at the First Annual Meeting, North American Spine Society, Lake George, New York, 1986.
- Farfan HF, Huberdeau RM, Dubow HI. Lumbar intervertebral disc degeneration: The influence of geometrical features on the pattern of disc degeneration—A post-mortem study. *J Bone Joint Surg [Am]* 1972;54:492-510.
- Federative Committee on Anatomic Terminology. *Terminologia Anatomica*. Stuttgart: George Thieme Verlag. 1998:27.
- Herzog RJ. The radiologic assessment for a lumbar disc herniation. *Spine* 1996;21:19.5-38S.
- Hirsch C, Schajowicz F. Studies in structural changes in the lumbar annulus fibrosus. *Acta Orthop Scand* 1952;22:184-231.
- International Anatomical Nomenclature Committee approved by Eleventh International Congress of Anatomists. *Nomina Anatomica*. 5th ed. Baltimore, MD: Waverly Press, 1983:A23.
- Jarvik JG, Haynor DR, Koepsell TD, et al. Interreader reliability for a new classification of lumbar disc abnormalities. *Acad Radiol* 1996;3:537-44.
- Kieffer SA, Stadlan EM, Mohandas A, et al. Discographic-anatomical correlation of developmental changes with age in the intervertebral disc. *Acta Radiol [Diagn] (Stockholm)* 1969;9:733-9.
- Masaryck TJ, Ross JS, Modic MT, et al. High resolution MR imaging of sequestered lumbar intervertebral discs. *AJNR Am J Neuroradiol* 1988;9: 351-8.
- Milette PC. The proper terminology for reporting lumbar intervertebral disk disorders. *AJNR Am J Neuroradiol* 1997;18:1859-66.
- Milette PC, Fontaine S, Lepanto L, et al. Differentiating lumbar disc protrusions, disc bulges, and discs with normal contour but abnormal signal intensity. *Spine* 1999;24:44-53.
- Milette PC, Melançon D, Dupuis PR, et al. A simplified terminology for abnormalities of the lumbar disc. *Can Assoc Radiol J* 1991;42:319-25.
- Mink JH. Terminology of lumbar spine disorders, the problem . . . and a solution. Burlingame, CA: California Managed Imaging Medical Group Publication, 1993.
- Modic MT. Degenerative disorders of the spine. In: *Magnetic Resonance Imaging of the Spine*. New York: Yearbook Medical, 1989:83-95.
- Modic MT, Herfkens RJ. Intervertebral disk: Normal age-related changes in MR signal intensity. *Radiology* 1990;177:332-4.
- Modic MT, Masaryck TJ, Ross JS, et al. Imaging of degenerative disk disease. *Radiology* 1988;168:177-86.
- Nathan H. Osteophytes of the vertebral column. An anatomical study of

- their development according to age, race, and sex, with consideration as to their etiology and significance. *J Bone Joint Surg Am* 1962;44:243–68.
33. Nordby EJ, Brown, MD, Dawson ED, et al, eds. *A Glossary on Spinal Terminology*. Chicago: American Academy of Orthopaedic Surgeons, 1985: 31–2.
  34. Pritzker KPH. Aging and degeneration of the lumbar intervertebral disk. *Orthop Clin North Am* 1977;8:65–77.
  35. Resnick D, Niwayama G. Degenerative disease of the spine. In: Resnick D, ed. *Diagnosis of Bone and Joint Disorders*. ed 3. Philadelphia: WB Saunders, 1995:1372–1462.
  36. Sauser DD, Goldman AB, Kaye JJ. Discogenic vertebral sclerosis. *Can Assoc Radiol J* 1978;29:44–50.
  37. Schmorl G, Junghans H. *The Human Spine in Health and Disease*. 2nd American ed. Transl. by EF Besemann. New York: Grune and Stratton, 1971:141–8, 186–98.
  38. Sether LA, Yu S, Haughton VM, et al. Intervertebral disk: Normal age-related changes in MR signal intensity. *Radiology* 1990;177:385–8.
  39. Taveras JM. Herniated intervertebral disk: A plea for a more uniform terminology. *AJNR Am J Neuroradiol* 1989;10:1283–4.
  40. Twomey LT, Taylor JR. Age changes in lumbar intervertebral discs. *Acta Orthop Scand* 1985;56:496–9.
  41. Twomey LT, Taylor JR. Age changes in lumbar vertebrae and intervertebral discs. *Clin Orthop* 1987;224:97–104.
  42. United States Department of Health, Human Services. Publication no. (PHS)91–1260, *International Classification of Diseases Ninth Revision, Clinical Modification Fifth Edition*, Washington, DC, 1998; adapted and published by Practice Management Information Corporation, Los Angeles, and St. Anthony's Publishing Company, Alexandria, VA, 1999.
  43. Williams AL. CT diagnosis of degenerative disc disease, the bulging annulus. *Radiol Clin North Am* 1983;21:289–300.
  44. Williams AL, Haughton VM, Daniels DL, et al. Differential CT diagnosis of extruded nucleus pulposus. *Radiology* 1983;148:141–8.
  45. Wiltse LL, Berger PE, McCulloch JA. A system for reporting the size and location of lesions of the spine. *Spine* 1997;22:1534–7.
  46. World Health Organization. *Manual of the International Classification of Diseases, Injuries, and Causes of Death*. Geneva, Switzerland: World Health Organization, 1977.
  47. Yasuma T, Koh S, Okamura T, et al. Histologic changes in aging lumbar intervertebral discs. *J Bone Joint Surg [Am]* 1990;72:220–9.
  48. Yasuma T, Makino E, Saito S, et al. Histologic development of intervertebral disc herniation. *J Bone Joint Surg [Am]* 1986;68:1066–73.
  49. Yu S, Haughton VM, Sether LA, et al. Annulus fibrosus in bulging intervertebral disks. *Radiology* 1988;169:761–3.

## ■ Appendix

### Chairpersons of the Task Forces

David F. Fardon, MD  
Orthopedic Surgeon  
Knoxville Orthopedic Clinic  
Knoxville, TN USA

Pierre C. Milette, MD  
Neuroradiologist  
Clinical Professor of Radiology  
Université de Montréal  
Montreal, Quebec Canada

### Clinical Task Force

Tom Faciszewski, MD  
David F. Fardon, MD  
Steven R. Garfin, MD  
Scott Haldeman, MD, PhD  
Neil Kahanovitz, MD  
Volker K.H. Sonntag, MD

### Imaging Task Force

Brigitte Appel, MD  
Jean-François Bonneville, MD  
Marco Leonardi, MD

Pierre C. Milette, MD  
Jeffrey S. Ross, MD  
Alan L. Williams, MD  
Jan T. Wilmsink, MD, PhD

### Members of the Task Forces

Brigitte Appel, MD  
Neuroradiologist  
Head of Neuroradiology-CT-MRI  
A.Z. Middelheim  
Antwerp, Belgium

Jean-François Bonneville, MD  
Neuroradiologist  
Professor of Neuroradiology  
Université de Franche-Comté  
Besancon, France

Tom Faciszewski, MD  
Orthopedic Surgeon  
Marshfield Clinic  
Marshfield, WI USA

Steven R. Garfin, MD  
Orthopedic Surgeon  
Professor of Orthopedic Surgery  
University of California, San Diego  
San Diego, CA USA

Scott Haldemann, MD, PhD  
Neurologist  
Associate Clinical Professor of Neurology  
University of California, Irvine  
Irvine, CA USA

Neil Kahanovitz, MD  
Orthopedic Surgeon  
Anderson Orthopedic Clinic  
Arlington, VA USA

Marco Leonardi, MD  
Neuroradiologist  
Head of Neuroradiology  
Ospedale Bellaria  
Bologna, Italy

Jeffrey S. Ross, MD  
Neuroradiologist  
Head of Radiology Research  
Cleveland Clinic  
Cleveland, OH USA

Volker K.H. Sonntag, MD  
Neurological Surgeon  
Barrow Neurological Institute  
Phoenix, AZ USA

Alan L. Williams, MD  
Neuroradiologist  
Professor of Radiology  
St. Louis University  
St. Louis, MO USA

Jan T. Wilmink, MD, PhD  
Neuroradiologist  
Professor of Neuroradiology  
University of Maastricht  
Maastricht, The Netherlands

Jerrold H. Mink, MD  
Radiologist  
Tower Imaging Medical Group  
Los Angeles, CA USA

John D. Simmons, MD  
Abercrombie Radiology  
Knoxville, TN USA

***Consultants and Advisors***

Robert E. Florin, MD  
Neurological Surgeon  
Clinical Professor of Neurosurgery  
University of Southern California  
Los Angeles, CA USA

Richard J. Herzog, MD  
Neuroradiologist  
Chief of Teleradiology  
Hospital for Special Surgery  
New York, NY USA

*Address correspondence and reprint requests to*

Pierre C. Milette, MD  
Department of Radiology  
CHUM—Hôpital Saint-Luc  
1058, Saint-Denis Street  
Montreal, QC, Canada  
H2X 3J4  
or David F. Fardon, MD  
Knoxville Orthopedic Clinic  
1128 Weisgarber Road  
Knoxville, TN 37922