2.1 Lateral variation of the supraorbital craniotomy

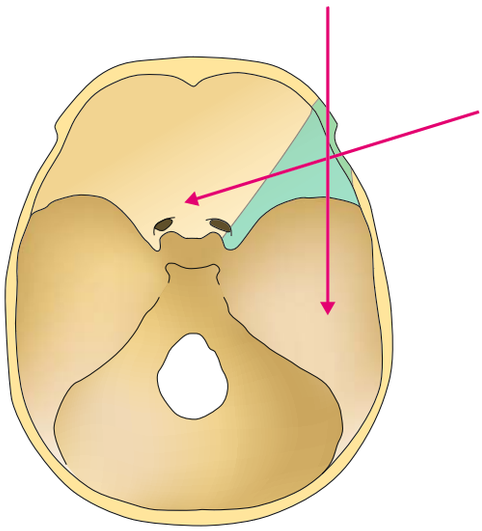

Fig. 2.1.1 *Schematic picture demonstrating the aim of the lateral variation of the supraorbital craniotomy. Removal of the lesser sphenoid wing provides a pterional surgical corridor for broad frontotemporal exploration.*

The essence of the lateral variation of the supraorbital craniotomy is not only the more lateral placement of the keyhole craniotomy but also a partial removal of the lesser sphenoid wing, also exposing the frontal and temporal dura mater (Fig. 2.1.1). The pterional surgical corridor exposes the anteromedial temporal lobe, frontal latero-basal cortex, the Sylvian fissure and the suprasellar pyramid more from the side. This allows safe dissection of the anterior part of the cavernous sinus and the paraclinoid region. Moreover, by removing the anterior clinoid process, the paraclinoid segment of the internal carotid artery can also be exposed without opening the venous chamber of the cavernous sinus.

In the following, the surgical technique of the lateral supraorbital approach is described.

Ipsilateral	Midline	Contralateral
Roof and lateral wall of the orbit	Crista Galli	Orbital roof
Anterior clinoid process	Olfactory groove	Anterior clinoid process
Posterior clinoid process	Planum sphenoidale	Basal frontal lobe
Chamber of the CS	Tuberculum sellae	Sylvian fissure
Latero-basal frontal lobe	Chiasm	Temporal pole
Sylvian fissure	Lamina terminalis	CN I, CN II, CN III
Anteromedial temporal lobe	Pituitary stalk	ICA, OphtA, PCoA, AChA
Crus cerebri	ACoA	A1, A2, M1, M2, P1, SCA, incl. perforators
CN I, CN II, CN III, CN IV	Distal BA, incl. perforators	
CN V, CN VI		
ICA, OphtA, PCoA, AChA, incl. perforators		
A1, A2, M1, M2, P1, P2, SCA		

Table 2.1.1 *Anatomical structures approached through the lateral supraorbital craniotomy.*

Surgical technique

1. Patient positioning

The patient is positioned supine. If used, the single pin of the Mayfield clamp should be placed on the opposite side, allowing free manipulation during surgery. The pins should not be placed in the temporalis muscle to avoid instability of the system and postoperative temporal hematoma.

Step 1

With the patient in a supine position, the head is elevated approximately 15° above the level of the thorax. This maneuvre facilitates the cerebral venous drainage and provides effective decompression of the main cervical vessels, larynx and ventilation tube (Fig. 2.1.2).

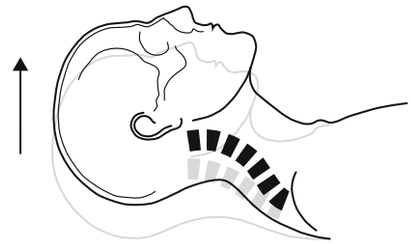

Fig. 2.1.2

Step 2

Ca. 20° retroflexion supports the gravity-related self-retraction of the frontal lobe. As the lateral variation is used for approaching the lateral suprasellar region and the CS, the degree of retroflection is usually less than that for supraorbital craniotomy (Fig. 2.1.3).

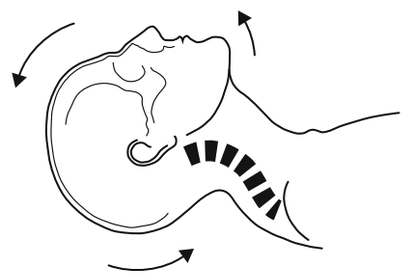

Fig. 2.1.3

Step 3

Thereafter, the head is rotated 30° to 75° to the contralateral side according to the precise location of the lesion. Compared to supraorbital craniotomy, the more pterionally situated lateral variation requires more rotation: for the lateral CS, a rotation of ca. 40° and for the olfactory groove that of 80° is sufficient. Note that right-handed surgeons using a left-sided craniotomy need more rotation to provide an efficient working position (Fig. 2.1.4).

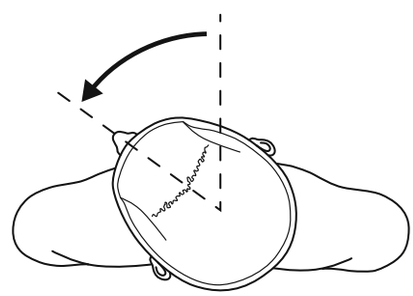

Fig. 2.1.4

Step 4

Similar to the supraorbital craniotomy, the head may be lateroflected ca. 10° to the contralateral side, allowing an efficient working position for the surgeon (Fig. 2.1.5).

Fig. 2.1.5

2. Anatomical landmarks and orientation

For an optimal skin incision, the important anatomical landmarks of the osseous skull such as the glabella, frontal paranasal sinus, supraorbital foramen, temporal line, frontobasis, impression of the lesser sphenoid wing and the zygomatic arch are precisely defined and marked. Note the course of the supraorbital nerves and artery, and the frontal branch of the facial nerve (Fig. 2.1.6).

After positioning, the individual optimum line of the skin incision is marked with the pen, placed 5–10 mm laterally to the supraorbital foramen running within and extending some millimeters over the lateral edge of the eyebrow. The midpoint of this skin incision usually corresponds to the temporal line (Fig. 2.1.6). If the eyebrow appears thin, the laterally placed skin incision may give a suboptimal cosmetic result. In this case the skin incision should be performed behind the frontotemporal hairline or in a prominent wrinkle. The eyelids are protected carefully and the skin is disinfected with alcohol solution.

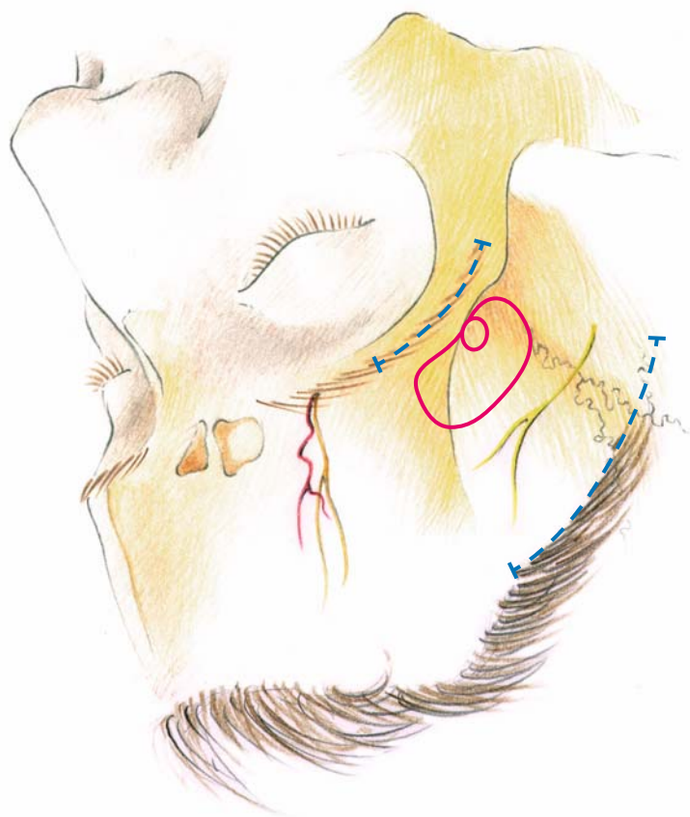

Fig. 2.1.6 *Definition of the craniotomy according to the anatomical landmarks of the frontotemporal region. The skin incision should be made within the eyebrow, extending some millimeters over its lateral edge. In the case of a thin and non-dominant eyebrow, the incision can be also concealed behind the hairline.*

3. Craniotomy

Step 1

Right side. The skin incision begins about 5–10 mm laterally from the supraorbital incisura and is performed within the eyebrow, extending a few millimeters over the lateral projection of the brow into the frontozygomatic area. After skin incision the subcutaneous tissue is dissected in a frontal, frontolateral direction (Fig. 2.1.7).

Fig. 2.1.7

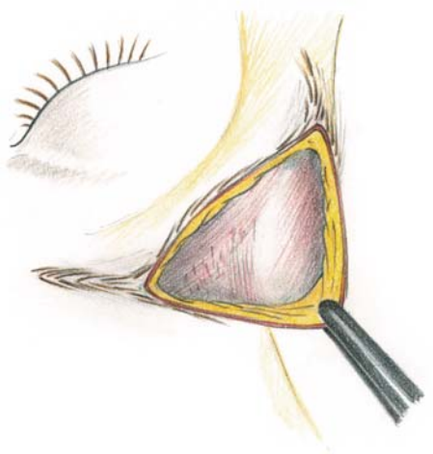

Step 2

Thereafter, the flaps are retracted, pushed gently up towards the orbit and retracted strongly downwards in a frontal direction to achieve optimal exposure of the occipitofrontal, orbicular and temporal muscles. Compared with the supraorbital craniotomy, the lateral variant offers more exploration of the temporalis muscle (Fig. 2.1.8).

Fig. 2.1.8

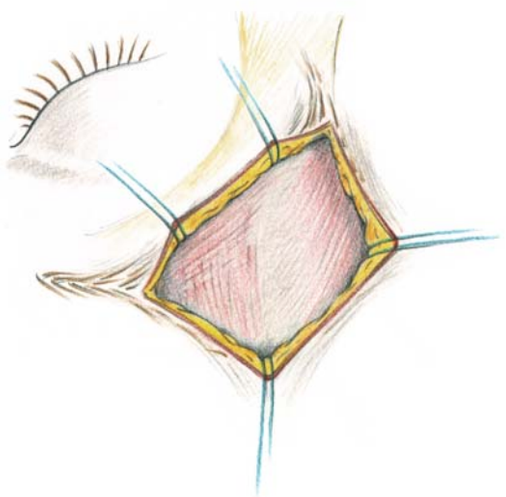

Step 3

The frontal belly of the occipitofrontal muscle is cut parallel to the orbital rim in a medial to lateral direction and the temporal muscle is stripped from its bony insertion with a monopolar electrode knife. Compared with the supraorbital craniotomy, the temporal muscle should be more mobile, allowing exposure of the pterion. Hemostasis should be performed rapidly and with precision (Fig. 2.1.9).

Fig. 2.1.9

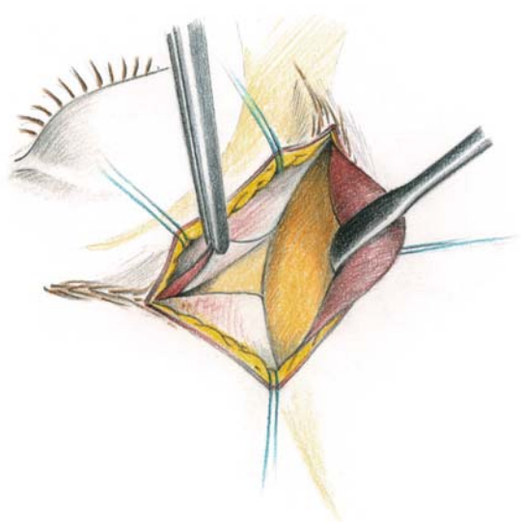

Step 4

The temporal muscle is then forcibly retracted laterally, exposing the impression of the lesser sphenoid wing between the frontal and temporal skull base. The frontal muscular layer is retracted forcefully downwards with strong, careful stitches. After soft tissue dissection, a single frontobasal burr hole is drilled just posterior to the temporal line with a high-speed drill (Fig. 2.1.10).

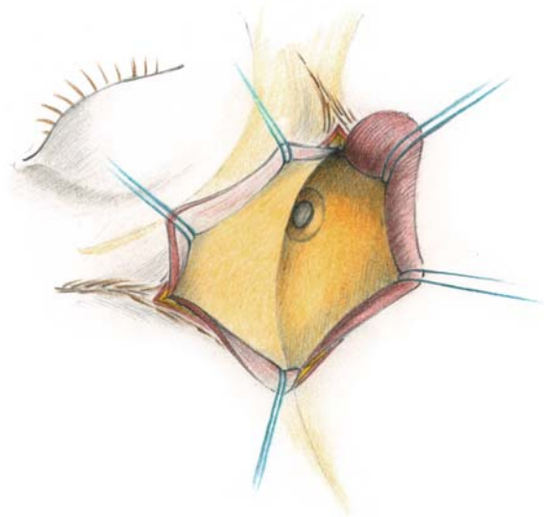

Fig. 2.1.10

Step 5

The hole is enlarged a little with fine punches. After mobilization of the dura mater, a ca. 10 mm long straight line is cut with a high-speed craniotome parallel to the orbital rim in a lateral to medial direction (Fig. 2.1.11).

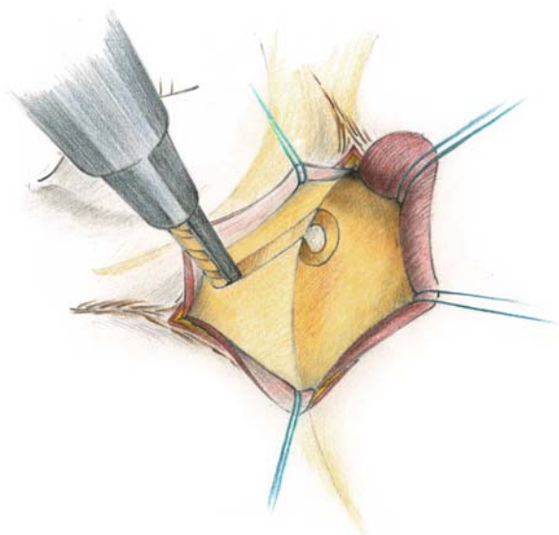

Fig. 2.1.11

Step 6

After the frontobasal cutting, a semicircular line is cut at first laterally from the burr hole, then to the medial border of the previously cut frontobasal line, creating a bone flap with a width of ca. 15–25 mm and a length of ca. 20–30 mm (Fig. 2.1.12).

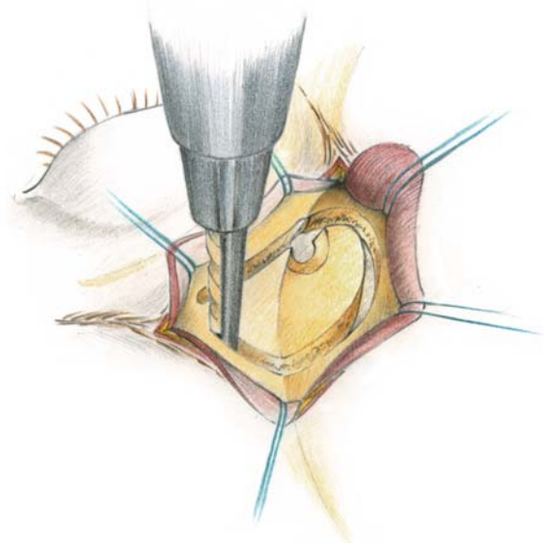

Fig. 2.1.12

Fig. 2.1.13

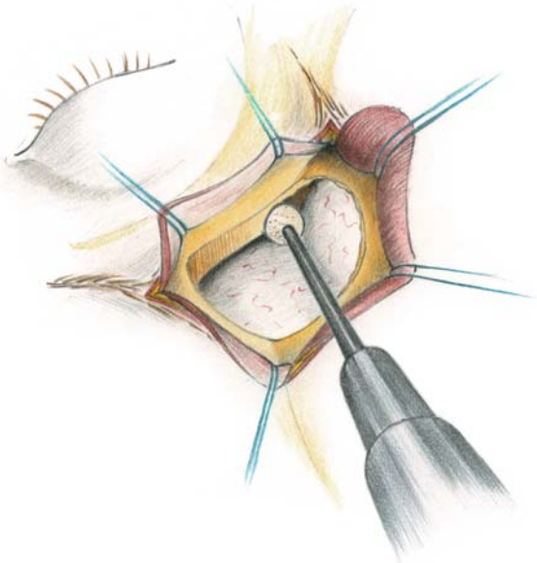

Step 7

After removal of the bone flap, the inner edge of the bone above the orbital rim and the lateral part of the lesser sphenoid wing are removed with a high-speed drill exposing the transition between the frontal and temporal dura mater. Small bony protrusions of the orbital roof should also be drilled extradurally to obtain optimal intradural exposure (Fig. 2.1.13).

Fig. 2.1.14

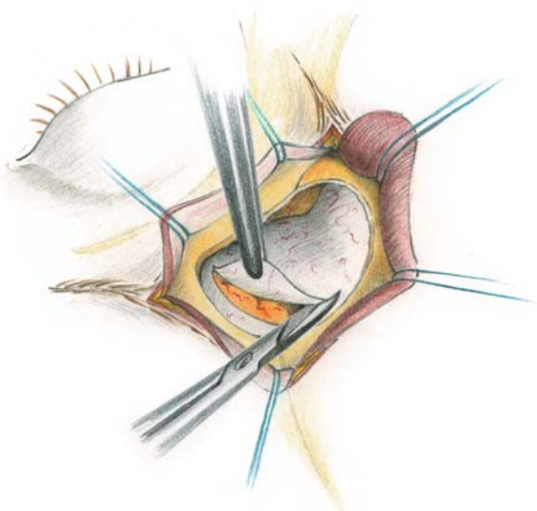

Step 8

After exposure of the frontotemporal dura mater, the durotomy should be performed in a curved fashion with its base towards the supraorbital rim exposing the Sylvian fissure between the frontal and temporal lobes (Fig. 2.1.14).

Fig. 2.1.15

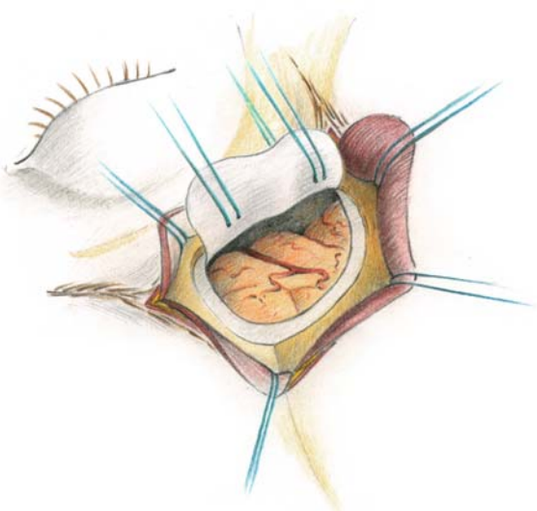

Step 9

The frontal and temporal lobes are exposed after opening the dura mater. The dural flap is fixed basally with holding sutures (Fig. 2.1.15).

4. Intradural dissection

Step 1

Right side. Dissection on fresh human cadaver; arterial vessels are filled with red colored latex solution. After withdrawing the bone flap, the lesser sphenoid wing is carefully removed with a fine high-speed diamond drill. After complete removal of the anterior clinoid process, the CN II and the paraclinoid segment of the ICA can be precisely observed. The covering dura mater of the anterior clinoid, which should be kept intact, forms the so-called proximal and distal rings of the carotid artery. The proximal dural ring separates the venous compartments of the CS from the paraclinoid area covering the CN III. The dural sheet of the distal ring encircles the ICA and the CN II and also forms the falciform ligament of the optic nerve (Fig. 2.1.16).

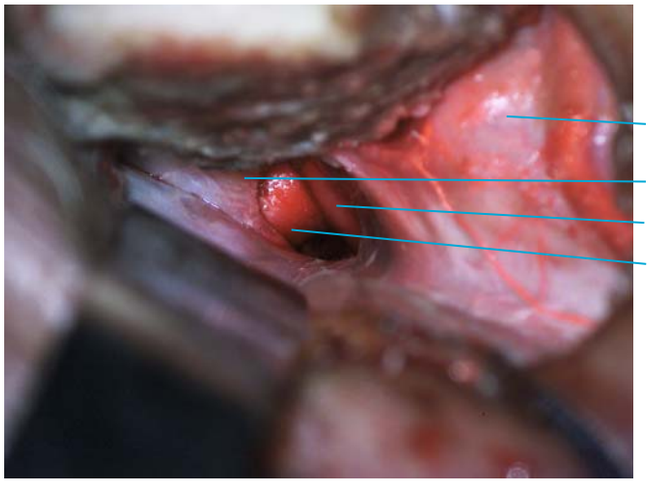

Fig. 2.1.16

Step 2

After opening the dura mater, the carotid cistern and the medial part of the Sylvian fissure are dissected. After removal of CSF, the frontal and temporal lobes deflate, allowing intradural dissection with minimal brain retraction. Note the opening of the OPCA window with fine microscissors. The frontal lobe is gently retracted with a spatula (Fig. 2.1.17).

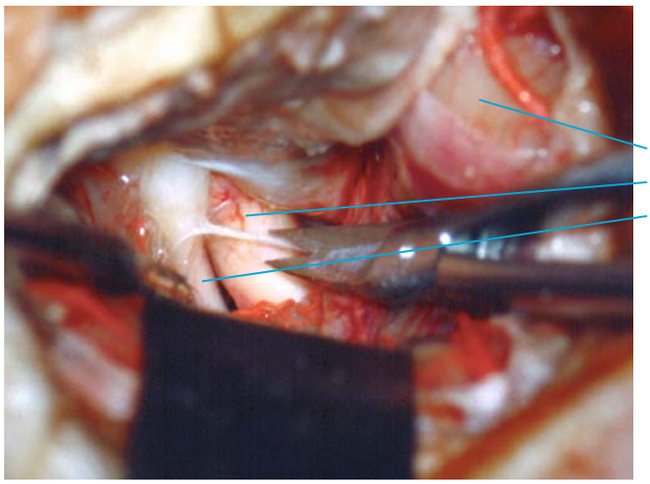

Fig. 2.1.17

Step 3

Observation of the lateral suprasellar pyramid. Compared to the supraorbital craniotomy, the suprasellar structures are visualized more from the lateral side; note the CN II, optic tract, ICA and CN III. Using this lateral-pterional surgical corridor, retraction of the temporal lobe with a dissector is necessary for optimal exposure of the suprasellar region (Fig. 2.1.18).

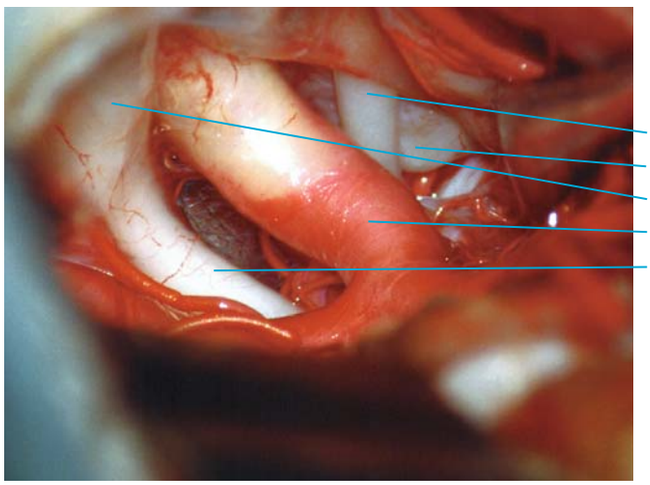

Fig. 2.1.18

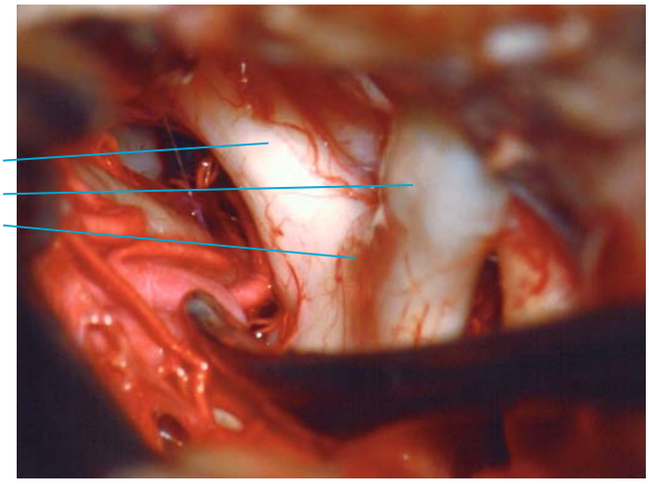

Fig. 2.1.19

Step 4

Dissecting in the medial direction, the chiasm and both optic nerves are observed. Note the contralateral CN II; the dissector is pointing to the ACoA complex and the opposite A1 segment of the ACA (Fig. 2.1.19).

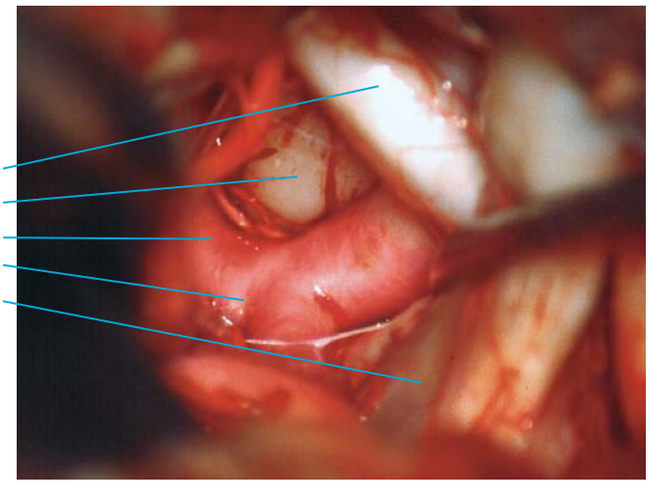

Fig. 2.1.20

Step 5

Observation of the contralateral ICA bifurcation. Through the lateral-pterional approach, the chiasm and the opposite CN II must be retracted to reveal the ICA; a clear disadvantage compared to the subfrontal supraorbital approach. Note the opposing temporal lobe behind the ICA; the MCA disappears within the opposite Sylvian fissure. Note the lamina terminalis (Fig. 2.1.20).

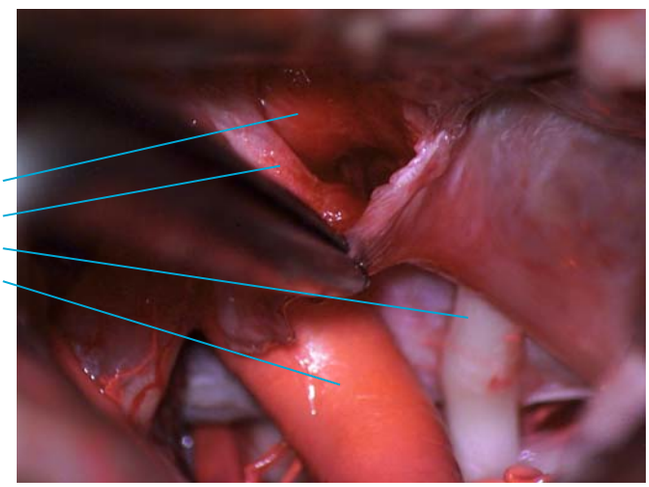

Fig. 2.1.21

Step 6

Approaching again from the ipsilateral side, the covering dura mater of the previously removed anterior clinoid process is incised and retracted with microforceps, allowing a clear depiction of the distal dural ring encircling the ICA. Note the supra- and paraclinoid segments of the ICA and the CN III (Fig. 2.1.21).

Step 7

The roof of the cavernous sinus is opened and retracted medially with microforceps. The proximal ring or so-called carotico-clinoid ligament appears medial to the CN III, closing the venous chamber of the cavernous sinus. Note the paraclinoid ICA and the ICA bifurcation within the subarachnoid space (Fig. 2.1.22).

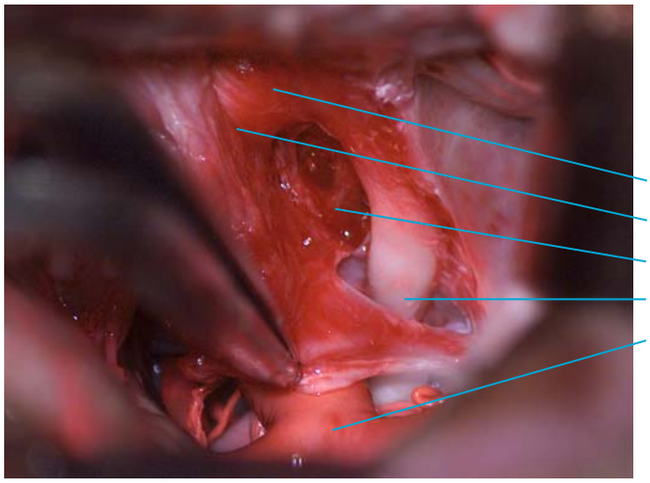

Fig. 2.1.22

Step 8

After resection of the proximal ring and the entire roof of the cavernous sinus, the chamber of the cavernous sinus is opened. Note the supraclinoid, paraclinoid and intracavernous segments of the ICA. The CN III and CN IV disappear into the superior orbital fissure. The BA can be observed within the posterior fossa medial from the subarachnoidal portion of the CN III (Fig. 2.1.23).

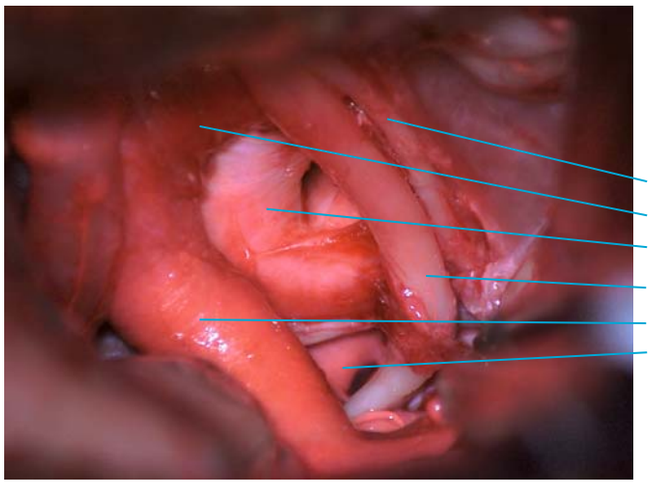

Fig. 2.1.23

Step 9

After partial removal of the lateral dural wall of the cavernous sinus, the posterior knee of the ICA is observed. After gentle retraction of the sensitive CN IV, the venous chamber of the posterior cavernous sinus can be seen. Note the CN III appearing behind the PCA and disappearing into the superior orbital fissure (Fig. 2.1.24).

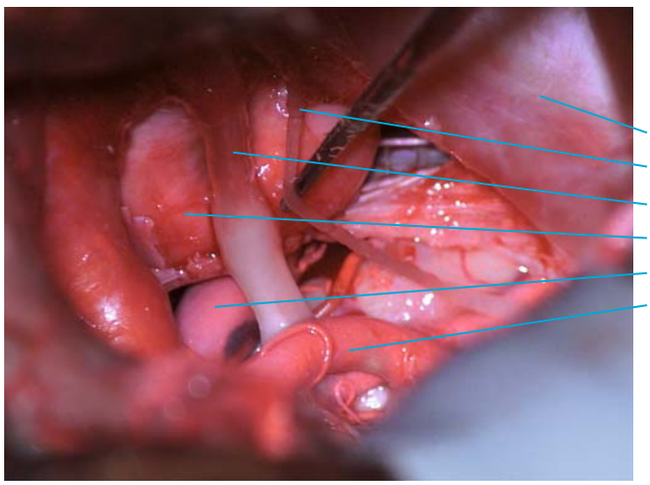

Fig. 2.1.24

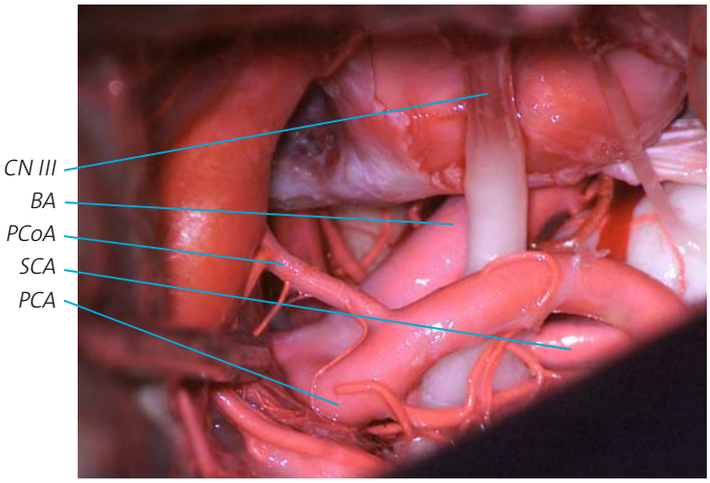

Fig. 2.1.25

Step 10

Observation of the subarachnoidal and intracavernous segments of the CN III after opening the cavernous sinus. Note the SCA, the P1 and P2 segments of the PCA. The PCoA connects the ICA to the PCA; in this case the P1 segment is more prominent than the PCoA. Note the laterally displaced BA within the posterior fossa. The supraclinoid ICA is gently retracted with a microsucker (Fig. 2.1.25).

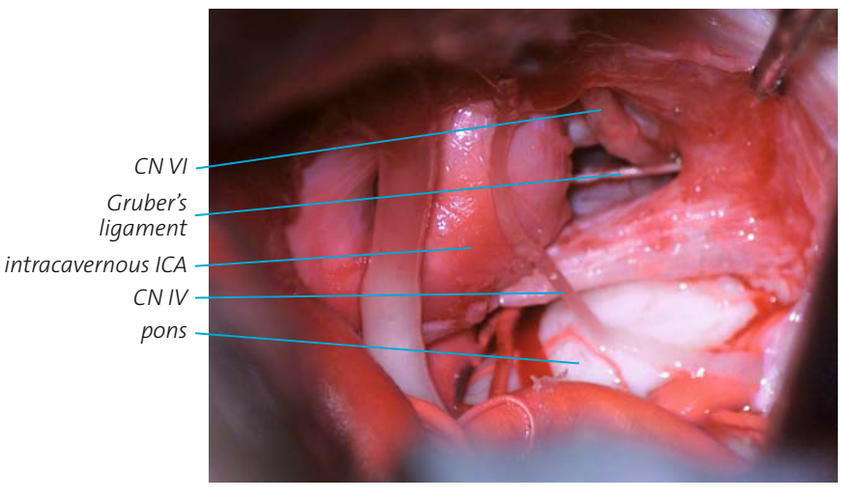

Fig. 2.1.26

Step 11

Observation of the posterior chamber of the cavernous sinus. Note the CN VI running within the Dorello canal, between the clivus and Gruber's petroclival ligament. Behind the clivus, the anterior surface of the pons can also be seen (Fig. 2.1.26).

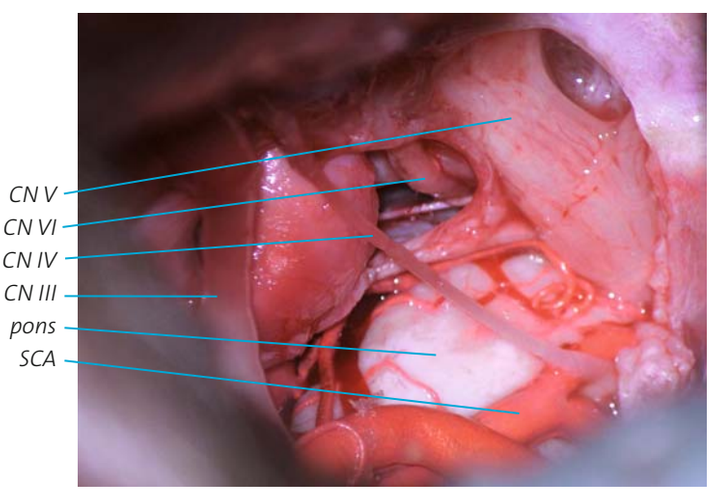

Fig. 2.1.27

Step 12

After additional removal of the lateral sinus wall, the entire cavernous sinus can be approached via the lateral supraorbital craniotomy. Note the intracavernous ICA, CN III, CN IV, CN V and the CN VI. The ventral surface of the pons with the superior cerebellar and posterior cerebral arteries appear in a special transcavernous aspect. Note the division of the SCA near to the CN IV (Fig. 2.1.27).

5. Dura, bone and wound closure

After completion of the intracranial procedure, the intradural space is filled with artificial CSF and the dura closed with sutures. The closure should be made watertight to avoid postoperative CSF fistula. If tension or dehiscence has developed in the dural plane, a piece of muscle can be sewn into the dural closure. A plate of gelfoam is placed extradurally and the bone flap fixed with a titanium plate. Note that the bone flap should be tightly fixed both medially and frontally to achieve optimal cosmetic results. In the case of large bony defect areas after removal of the lesser sphenoid wing, we often use a large-sized titanium plate avoiding a cosmetically disturbing groove after wound healing within the temporal area. Alternatively, bone cement can be used covering the bony defect. After final verification of hemostasis, the muscular and subcutaneous layers are closed with interrupted sutures and the skin with a running intracutaneous suture or sterile adhesive tape. No suction drain is necessary.

Potential errors and their consequences

- Insufficient preoperative planning and positioning of the patient with subsequent insufficient exposure of the surgical field and significant deterioration in efficiency of excising the lesion. Planning and positioning is the task of the surgeon!
- The skin incision does not follow the orbital rim causing a suboptimal cosmetic result.
- Penetration of the orbit during burr hole trephination with postoperative orbital hematoma and swelling.
- Inadequate removal of the lesser sphenoid wing with limited temporal extension of the craniotomy and limited exposure of the Sylvian fissure.
- Overlooked, but often unavoidable, injury to the dura during craniotomy. In some cases, implantation of plastic material may be necessary.
- Penetration of the orbit during extradural removal of osseous extensions of the orbital roof and the lesser sphenoid wing with subsequent postoperative orbital hematoma and swelling.
- Inadequate removal of CSF after durotomy with contusion of the frontal or temporal lobe due to spatula pressure.
- Injuries to numerous nerves and vessels within the parasellar region during microsurgical manipulation with postoperative neurological deterioration.

- Inadequate intracranial hemostasis with postoperative rebleeding into the surgical field.
- Inadequate dural closure with a postoperative CSF fistula.
- Inadequate positioning and fixation of the bone flap resulting in poor cosmetic results.
- Inadequate hemostasis during wound closure with postoperative soft tissue hematoma.

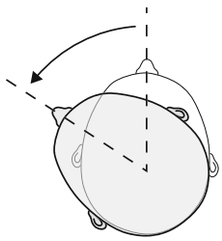

Fig. 2.1.28

Tips and tricks

- Take time for preoperative planning and positioning of patients. The reward is an excellent overview of the target area and an efficient working position.

- Make a careful anatomical orientation and use the three steps of marking with a sterile pen: 1. osseous structures and nerves; 2. placement of craniotomy; 3. skin incision.

- Compared to the supraorbital craniotomy, the lateral supraorbital approach requires more head rotation during positioning (Fig. 2.1.28).

- If the eyebrow is not dominant, the skin incision may be performed behind the frontotemporal hairline or in a skin crease to achieve optimal cosmetic results (Fig. 2.1.29).

- During soft tissue dissection, the frontal muscle should be forcibly retracted downwards in a frontal direction with two or three sutures providing sufficient overview of the frontal bone. Exposure and mobilisation of the frontal and orbital muscles upwards should be restricted to the necessary minimum to prevent postoperative periorbital hematoma. Compared with the supraorbital craniotomy, the temporal muscle must be retracted more forcibly to the lateral side, allowing exposure of the lesser sphenoid wing. However, note careful retraction to prevent postoperative necrosis (Fig. 2.1.30).

- To avoid penetration of the orbit, take care of the placement of the burr hole and direction of the burring procedure (Fig. 2.1.31).

- Stages of craniotomy (Fig. 2.1.32): 1. burr hole trephination; 2. frontobasal cutting parallel to the orbital rim; 3. sawing in a semi-

Fig. 2.1.29

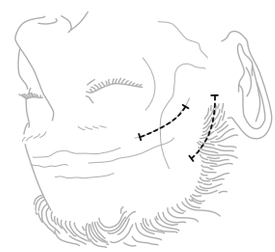

Fig. 2.1.30

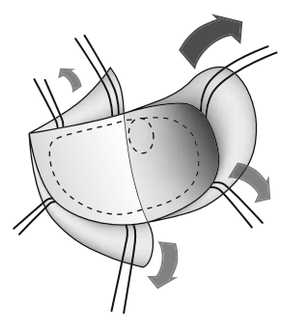

Fig. 2.1.31

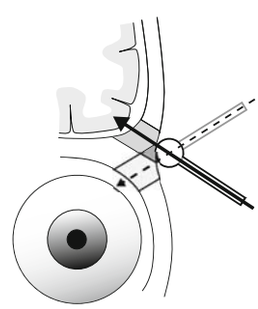

Fig. 2.1.32

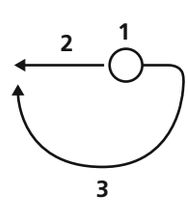

Fig. 2.1.33

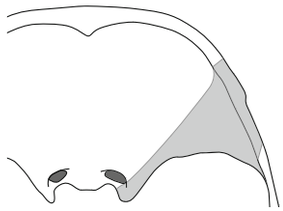

Fig. 2.1.34

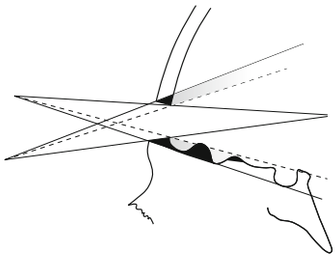

Fig. 2.1.35

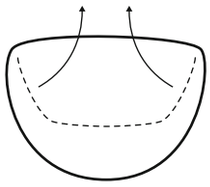

Fig. 2.1.36

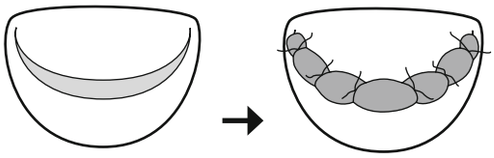

Fig. 2.1.37

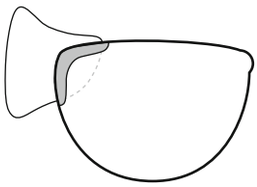

Fig. 2.1.38

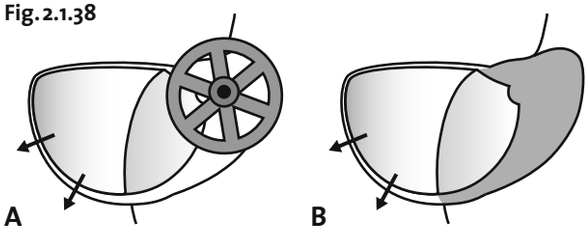

circular fashion from the burr hole, at first in a lateral direction then to the medial edge of the first craniotomy line.

- Drilling the lesser sphenoid wing allows a temporal extension of the supraorbital craniotomy (Fig. 2.1.33).

- Extradural drilling of the inner edge of the craniotomy rim and removal of the osseous extensions of the orbital roof offer an increased intracranial view during the later surgical procedure (Fig. 2.1.34).

- Opening the frontotemporal dura in a semilunar fashion is time-consuming but avoids unnecessary exploration of the frontal and temporal lobe (Fig. 2.1.35).

- After completion of the intradural dissection, dural closure should be made watertight to avoid postoperative CSF fistula. If tension or dehiscence has developed in the dural plane, a piece of muscle can be sewn into the dural closure (Fig. 2.1.36).

- According to the laterally placed approach, penetration of the frontal paranasal sinus is uncommon. If it happens, careful closure is recommended with bone wax, a flap of galea or with abdominal fat tissue (Fig. 2.1.37).

- During wound closure, the bone flap should be tightly fixed medially and frontally to achieve optimal cosmetic results (Fig. 2.1.38). In the case of large bony defect areas after removal of the lesser sphenoid wing, one should use a large titanium plate to cover the defect (A). Alternatively, bone cement can be used (B).

- The eyebrow skin incision should be closed with intracutaneous running sutures or with sterile adhesive tapes.

- On account of the limited skin incision and nontraumatic surgical technique, a suction drain is not required.